Journal of Chemical Neuroanatomy 114 (2021) 101958

Contents lists available at ScienceDirect

Journal of Chemical Neuroanatomy

journal homepage: www.elsevier.com/locate/jchemneu

The effect of erythropoietin and umbilical cord-derived mesenchymal stem cells on nerve regeneration in rats with sciatic nerve injury

Menekşe Ülger [a,*], Gülay Sezer [b], İrfan Özyazgan [c], Hakan Özocak [c], Arzu Yay [a], Esra Balcıoğlu [a], Betül Yalçın [a], Rümeysa Göç [d], Birkan Ülger [e], Tuğçe Merve Özyazgan [a], Birkan Yakan [a]

[a] Department of Histology and Embryology, Erciyes University, Faculty of Medicine, 38039, Kayseri, Turkey
[b] Department of Pharmacology, Erciyes University, Faculty of Medicine, 38039, Kayseri, Turkey
[c] Department of Plastic Reconstructive and Aesthetic Surgery, Erciyes University, Faculty of Medicine, 38039, Kayseri, Turkey
[d] Department of Histology and Embryology, Cumhuriyet University, Faculty of Medicine, 058140, Sivas, Turkey
[e] Department of Anesthesiology and Reanimation, Erciyes University, Faculty of Medicine, 38039, Kayseri, Turkey

ARTICLE INFO

Keywords:
Crush injury
Erythropoietin
Mesenchymal stem cell
Sciatic nerve

ABSTRACT

Objective: We aimed to investigate the effects of umbilical cord-derived mesenchymal stem cells and erythropoietin on nerve regeneration in the sciatic nerve 'crush injury' in a rat model.
Methods: Experimental animals were randomly divided into 5 groups: Crush Injury, Sham, Crush Injury + Erythropoietin, Crush Injury + Mesenchymal Stem Cell, Crush Injury + Erythropoietin + Mesenchymal Stem Cell groups. Crush injury made with bulldog clamp. Mesencyhmal stem cells delivered by enjection locally. Erythropoietin administered by intraperitoneally. On the 0th, 14th and 28th days, all groups underwent a sciatic functional index test. On 28th day, sciatic nerves were harvested and histopathological appearance, axon number and axon diameter of the sciatic nerves were evaluated with Oil Red O staining. Immunoreactivity of nerve growth factor, neurofilament-H and caspase-3 were determined by immunofluorescence staining in nerve tissue.
Results: In histopathological examination, axons and nerve bundles exhibiting normal nerve architecture in the Sham group. Crush Injury + Mesenchymal Stem Cell group has similar histological appearance to the Sham group. The number of axons were higher in the Mesenchymal Stem Cell groups compared to the Crush Injury group. Nerve growth factor immunoreactivity intensity was significantly lower in Crush Injury + Mesenchymal Stem Cell group compared to Crush Injury group. Neurofilament-H density was higher in the treatment groups when compared to the Crush Injury group.
Conclusions: In this study, it was found that umbilical cord-derived mesenchymal stem cells and erythropoietin treatments effects positively regeneration of crush injury caused by bulldog clamp in the sciatic nerve of rats.

1. Introduction

Peripheral nerves, consisting of motor, sensory and autonomic fascicles which composed of myelinated and unmyelinated nerve fibers (Raimondo et al., 2011; Evans, 2001), constitute the functional part of peripheral nervous system. In clinical practice peripheral nerve injury is a common medical problem caused by numerous conditions including sharp instruments, firearms, stretching, compression, limb injuries and iatrogenic injury (Lavasani et al., 2014). Among this causes, crush injury (CI) is the most common type of peripheral nerve injury (Taylor et al., 2008). Further, experimental model of nerve crush injury is relatively easy to apply. Additionally, in terms of peripheral nerve injury models, owing to its width and easy accessibility, sciatic nerve is mostly preferred in peripheral nerve injury models. (Gärtner et al., 2012; Haapaniemi et al., 1998). Considering all of these we use crush injury model in sciatic nerve for-with the purpose of make peripheral nerve injury in this study.

Although the peripheral nervous system has a significant regeneration capacity, spontaneous recovery is often weak. Due to this poor healing, peripheral nerve injury leads to complications such as impaired

* Corresponding author.
E-mail addresses: menekseulger@gmail.com (M. Ülger), gulayyszr@gmail.com (G. Sezer), ozyazganirfan@gmail.com (İ. Özyazgan), ozocakhakan@gmail.com (H. Özocak), arzu.yay38@gmail.com (A. Yay), esrabalcioglu79@hotmail.com (E. Balcıoğlu), by-by-2005@hotmail.com (B. Yalçın), rumeysayilmaz99@hotmail.com (R. Göç), birkanulger@hotmail.com (B. Ülger), tugceozyazgan@gmail.com (T.M. Özyazgan), yakanb@erciyes.edu.tr (B. Yakan).

https://doi.org/10.1016/j.jchemneu.2021.101958
Received 23 February 2021; Received in revised form 5 April 2021; Accepted 6 April 2021
Available online 14 April 2021
0891-0618/© 2021 Elsevier B.V. All rights reserved.

sensorimotor function and neuropathic pain, resulting in loss of function and impaired quality of life (Rosberg et al., 2005), and also in sequelae, especially in the case of large nerve defects (Raimondo et al., 2011; Petrova and Eva, 2018).

Following peripheral nerve injury, Wallerian degeneration occurs in the distal segment of the nerve. The broken nerve fibers are removed by Schwann cells and macrophages (He et al., 2016). With disruption of axoplasmic transport, the corresponding neurons degenerate (Wang et al., 2018). Then, Schwann cells migrate to the injury site after differentiation and proliferation. At injury site, differentiated Schwann cells form Büngner bands that provide pathways for axonal regeneration (Jessen and Mirsky, 2019). In addition, although there is an increase in local expression of neurotrophic factors at the injury site by Schwan cells, it is still not sufficient to regenerate axons effectively (He et al., 2016). Despite advances in microsurgical techniques aiming improve nerve regeneration, functional recovery is unsatisfactory (Li et al., 2013; Xiao and Tsutsui, 2013). As an example of surgical procedures, short-gap nerve defects are usually treated with an end-to-end anastomosis, while longer gap defects require grafts. As a graft, autologous nerve graft is still the first choice in management of nerve gap. However, it has disadvantages such as limited availability of donor tissue, sacrifice of functional nerve and neuroma formation (Chalfoun et al., 2006). For these reasons, innovative treatments that promote neuroprotection and neuroregeneration might be useful in favor of obtaining functional outcomes.

Stem cell transplantation has recently become an area of interest with the aim of ameliorating the neurodegeneration occurs after injury. As a stem cell subtype, mesenchymal stem cells (MSC) have some advantages including easy obtainability from different sources such as bone marrow, adipose tissue, amniotic fluid, umbilical cord and also exhibits a high potential in increasing peripheral nerve regeneration. Due to these properties, mostly due to latter, MSC attract attention for potential applications in peripheral nerve injury studies. In number of peripheral nerve regeneration models, it has been demonstrated that local implantation of bone marrow-derived mesenchymal stem cells (BM-MSC) give rise to various conditions such as neurotrophic factor secretion, microenvironment stabilization and immune. (Chen et al., 2007; Fernandes et al., 2018). Mesenchymal stem cells (MSC), obtained from easily accessible sources such as bone marrow, adipose tissue, amniotic fluid, umbilical cord, show high potential in increasing peripheral nerve regeneration and attract attention for potential applications in the peripheral nerve injury model. Among MSCs, umbilical cord stromal MSCs (UCS-MSC) are thought to be useful in experimental studies since they are easy to obtain and have been subject of many studies thanks to lack of ethical limitations regarding their usage. Moreover, in autologous and allogenic transplantation of UCS-MSC, they do not usually produce rejection responses and do not develop teratomas. Regarding studies, when UCS-MSC stimulated for neuronal transformation in vitro, they exhibit many structural features of differentiating to neuron or neuron precursors and begin to secrete various neurotrophic factors (Karahuseyinoglu et al., 2007; Weiss et al., 2006).

Although stem cell therapies can provide functional improvement after peripheral nerve injury, healing does not occur in a way that lead to full recovery. To improve therapeutic efficacy of MSC transplantation, it is important to improve MSC's homing ability towards therapeutic targets (Yang et al., 2015). One of the substances used for this purpose is a glycoprotein hormone that synthesized primarily from kidneys (Sasaki et al., 2000) and mainly responsible for production of erythrocytes (Bauer, 1995) erythropoietin (EPO). Thanks to wide distribution of EPO receptor, EPO shows impact on many different tissues like peripheral nerve and the others (Savino and Ciliberto, 2004). Beyond its well-known functions, it has been reported that EPO treatment enhance migration of MSCs to injury site (Liu et al., 2013) and also shows neuroprotective/neuroregenerative effect on different neuronal cells (Konishi et al., 1993; Morishita et al., 1997) as stimulates axonal development with its effect on Schwann cells (Geary et al., 2017). Besides it has been shown that in crush injuries, EPO can contribute more to nerve regeneration due to remains nerve intact compared to other injuries (Elfar et al., 2008).These neuroprotective/neuroregenerative activity exhibited by exerting anti-apoptotic, anti-inflammatory and anti-oxidant effect, repairing the blood-brain barrier, enabling mobilization and proliferation of neural stem cells, stimulating neurogenesis and angiogenesis, and protecting neural cells against hypoglycemia (Arcasoy, 2008).

In current study, we aimed to investigate the effects of UCS-MSC and EPO treatment on nerve regeneration after nerve crush injury model made with a clamp that applies constant pressure.

2. Materials and methods

2.1. Animals

For this study, 18/030 numbered approval of Erciyes University Animal Experts Local Ethics Committee was received on 14/02/2018 and was supported by Erciyes University Scientific Research Projects Unit with the project code numbered TTU-2018-8163. A total of 50 Wistar albino adult female rats weighing 130-150 g were used for experiment. All subjects were housed in separate cages and given ad libitum access to food and water under appropriate laboratory conditions (22 ± 2 °C, 12 h light/dark) during the experiment.

2.2. Isolation of MSCs from Wharton's jelly of umbilical cord

Umbilical cords were obtained from Erciyes University Hospitals Obstetrics and Gynecology operating unit following full-term cesarean births with the approval of Erciyes University Clinical Research Ethics Committee (Date: 04.04.2018, No:2018/182). Umbilical cords were taken into sterile Hanks Balanced Salt Solution, washed with sterile phosphate-buffered saline (PBS) and 70 % ethanol in the biosafety cabinet, respectively. After removing arteries, vein and amniotic membrane, the Wharton's jelly was stripped and cut into small pieces with the scalpel. PBS was added and centrifuged at 1500 rpm for 10 min. The pellet was cultured in 37 °C warmed Dulbecco Modified Eagle Medium (DMEM, Sigma) which was supplemented with 10 % Fetal Bovine Serum, 1% glutamax and 1% penicillin + streptomycin. The flasks were incubated in a carbon dioxide (CO2) incubator (Sanyo, Gunma, Japan) under 5 % CO2 and 95 % humidity conditions at 37 °C. The culture medium was changed every 2–3 days to allow cells multiply. The proliferated cells were detached from tissue culture flasks with 0.05 % Trypsin-EDTA and centrifuged at 1500 rpm for 5 min, then continued passaging.

2.2.1. Characterization of cells with surface markers

For characterization, some of the 3rd passage cells were investigated by the flow cytometry (BD FACS Aria III, San Jose, USA) to analyse the expression levels of positive (CD73, CD90, CD105) and negative surface markers (CD19 and HLA-DR). Antibodies were applied according to the manufacturer's instructions. Antibodies were; APC anti-human CD19 Antibody (Biolegend, 302211, 5/100 µL, USA), APC anti-human CD90 (Thy1) Antibody (Biolegend, 328114, 5/100 µL, USA), FITC anti-human CD105 Antibody (Biolegend, 323204, 5/100 µL, USA), FITC anti-human HLA-DR Antibody (Biolegend: 307604, 5/100 µL, USA) and PerCP/Cy5.5 anti-human CD73 (Ecto-5′-nucleotidase) Antibody (Biolegend, 344014, 5/100 µL, USA).

2.2.2. Adipogenic and osteogenic differentiation assays

To demonstrate the osteogenic and adipogenic transformation abilities of MSC, cells (passage 3) were seeded in 24-well plates and the next day the culture media was changed to adipogenic or osteogenic differentiation media (Rat Mesenchymal Stem Cell Functional Identification Kit SC020, R&D Systems) according to the manufacturer's instructions. The growth medium (control wells) and differentiation media

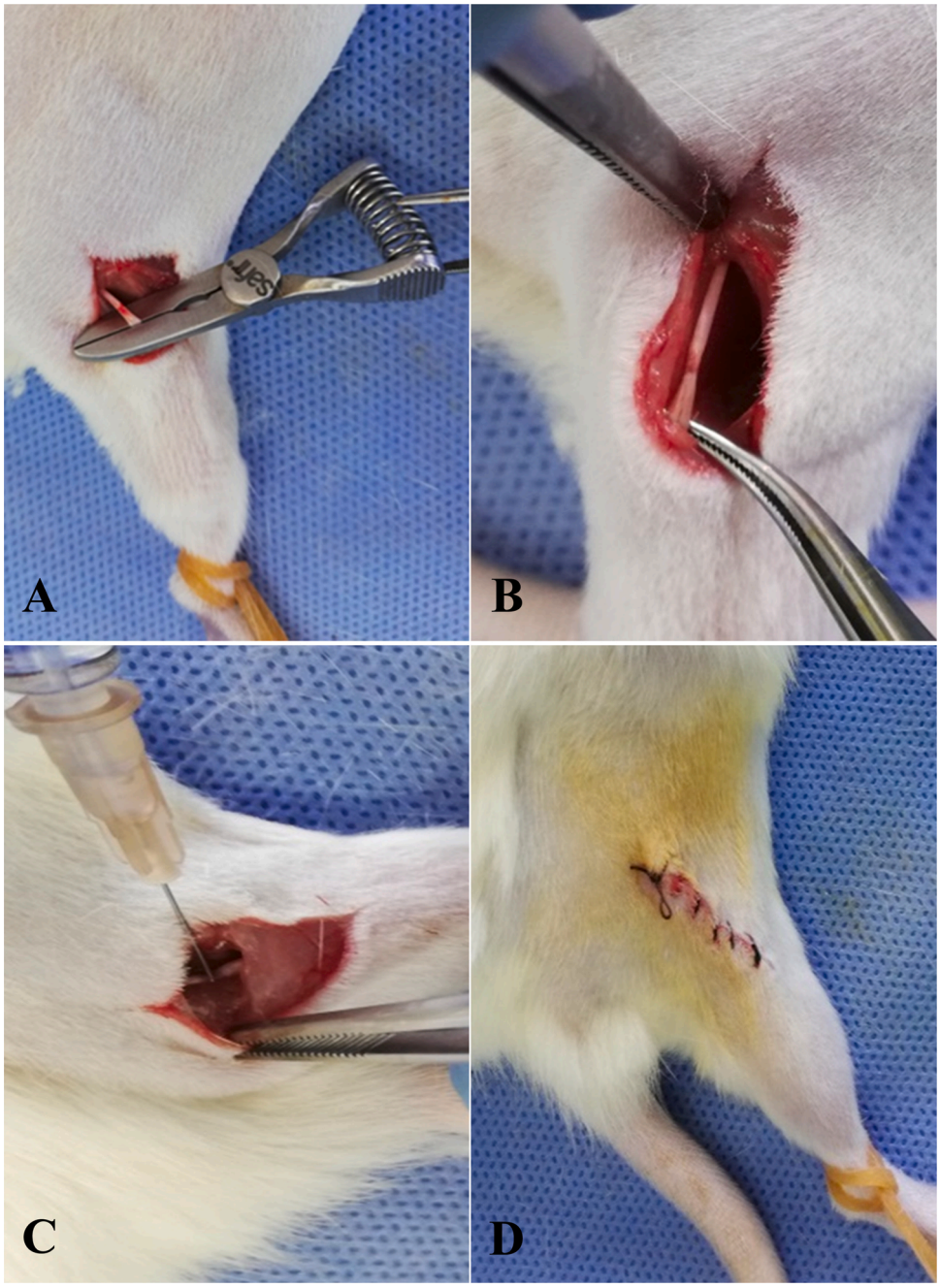

Fig. 1. These photos were taken with a camera. **A:** Crush injury was created with bulldog clamp**. B:** Thinning were observed macroscopically at the injury site. **C:** Stem cells were applied locally to the injury site. **D:** The skin was sutured with 4.0 nylon suture.

treatments were replenished every 2–3 days for 21 days. At the end of the period cells were fixed with 10 % formaldehyde solution and stained with Oil Red O (Sigma, Taufkirchen, Germany) and 2 % Alizarin Red S (Sigma, Taufkirchen, Germany) solutions to observe adipogenesis and osteogenesis, respectively. Photographs were taken under an inverted microscope.

In addition, immunofluorescent staining was also performed to observe the adipocyte marker FABP4 and osteocyte marker osteocalcin. Briefly, fixed cells were permeabilized with 0.3 % Triton X-100 and blocked with 10 % normal donkey serum in PBS for 1 h. Then the cells were incubated with Goat Anti-Mouse FABP4 polyclonal (R&D Systems) or Mouse Anti-Human Osteocalcin monoclonal antibodies (R&D Systems) overnight at 2−8 °C. After washing, cells were incubated with relevant seconder antibodies (NL557-conjugated donkey anti-goat and NL557-conjugated donkey anti-mouse secondary antibodies; R&D Systems) for 60 min at room temperature. After wash the cells three times with PBS, they were visualized by a fluorescence microscopy.

2.2.3. Labeling cells with PKH26

In order to show homing of locally transplanted MSCs at the target tissue in vivo, cells were stained with a fluorescent membrane dye PKH26 (Red Fluorescent Cell Linker Kit, Sigma, Taufkirchen, Germany) according to the manufacturer's instructions. The staining rate of cells was investigated by flow cytometry analysis. In addition, cells were treated with trypan blue and counted on Thoma cell counting chamber (Marienfeld, Marienfeld, Germany) to determine viability rate. Furthermore, a small amount of PKH26 stained cell suspension was dropped on a slide and immediately and immediately imaged and



Fig. 2. These photos were taken with a camera. **A:** Footprints were obtained on a white paper lying down through walking track. **B:** Footprints were measured with a caliper.

photographed under a fluorescence microscope (Olympus BX51, Japan).

2.3. Animal groups

50 rats were randomly divided into 5 groups (n = 10):

1 Sham group: The group with skin and muscle incision without nerve injury.
2 Crush injury (CI) group: The group with sciatic nerve CI without any treatment.
3 Crush injury + Mesenchymal Stem Cell (CI + MSC) group: The group with sciatic nerve CI and treated with $3,5 \times 10^5$/mL MSCs locally delivered to injured nerve in 50 µL Dulbecco's Phosphate Buffered Saline (DPBS) injected by Hamilton syringe.
4 Crush injury + EPO group (CI + EPO): The group with sciatic nerve CI treated by 5000 U/kg dose of rhEPO (PROCRIT; Amgen, Thousand Oaks, CA) administered intraperitoneally (ip) (El-Kordi et al., 2009).
5 Crush injury + EPO + Mesenchymal Stem Cell group (CI + EPO + MSC): The group with sciatic nerve CI and treated with EPO and MSCs as described above.

2.4. Surgical procedure

Rats were anesthetized by injection of ketamine hydrochloride (50 mg/kg ip) and 2% xylazine hydrochloride (5 mg/kg ip). Hairs in the medial side of right thigh were shaved. Rats were fixed on sterile cork boards in prone position. Then, surgical site disinfection was done with povidone-iodine. A 1,5 cm long oblique gluteal incision was made in right lower extremity following the projection of hip joint. The biceps femoris muscle was reached after skin edges were ruled out. The biceps femoris muscle was opened by blunt dissection and the sciatic nerve was reached by removing muscle edges. Later, sciatic nerve was released from surrounding tissues with thin-tip dissecting scissors. Crush injury was created with bulldog clamp in 1 cm proximal to bifurcation of tibial and peroneal nerves. As sciatic nerve crush injury models vary in the literature and there is a standardization problem, blunt pressure was applied for 90 s by atraumatic, arterial vascular bulldog clamp (Safir, S08−002-030) with 220 g clamping pressure. Thinning and whitening were observed macroscopically at the injury site. As seen in the Fig. 1C, when adjacent structures is removed from the nerve, a pocket-shaped space was formed by surrounding tissues around crush injured area. In MSC groups, MSCs were delivered on injured area with a single dose at $3,5 \times 10^5$/mL. It has been thought that MSCs wasn't flushed away and remained contacted thanks to this restricted space. The skin was sutured with 4.0 nylon suture. In EPO-treated groups, rhEPO administered with a single dose of 5000 U / kg ip after skin suturing (Fig. 1). No action was taken on the left thighs of the rats.

2.5. Sciatic functional index (SFI) assessment

SFI test was used to evaluate motor functional recovery. A 50 cm long, 8,2 cm wide and 12 cm deep walking corridor was created (Ozmen et al., 2002). The hind legs of the rats were painted with ink and allowed to freely walk in this corridor. Footprints were obtained on a white paper lying down through walking track. Each rat was made to walk until a clear footprint could obtained. Footprints were measured with a caliper (D&W). This SFI assessment were carried pre-crushing and 14th and 28th days post-crushing. (Fig. 2).

PL (Print Length): The distance from the heel to the third toe.

TS (Toe Spread): The distance between the first and the fifth toes.

IT (Intermediate Toe Spread): The distance between the second and fourth toes.

E: Experimental foot, N: Normal foot

These measurements were made from the footprints and calculations were made by placing them in the formula.

SFI = (−38.5 (EPL-NPL / NPL) + 109.5 (ETS-NTS / NTS) +13.3 (EITNIT / NIT)- 8.8)

Among values obtained between 0 and -100, while 0 indicates normal function and -100 complete functional loss (Bain et al., 1989).

2.6. Histological study

On the 28th day, the rats sacrificed under anesthesia. A 1 cm nerve including injury site was removed. For histopathological examination, samples were fixed in 4% paraformaldehyde. After tissue processing,

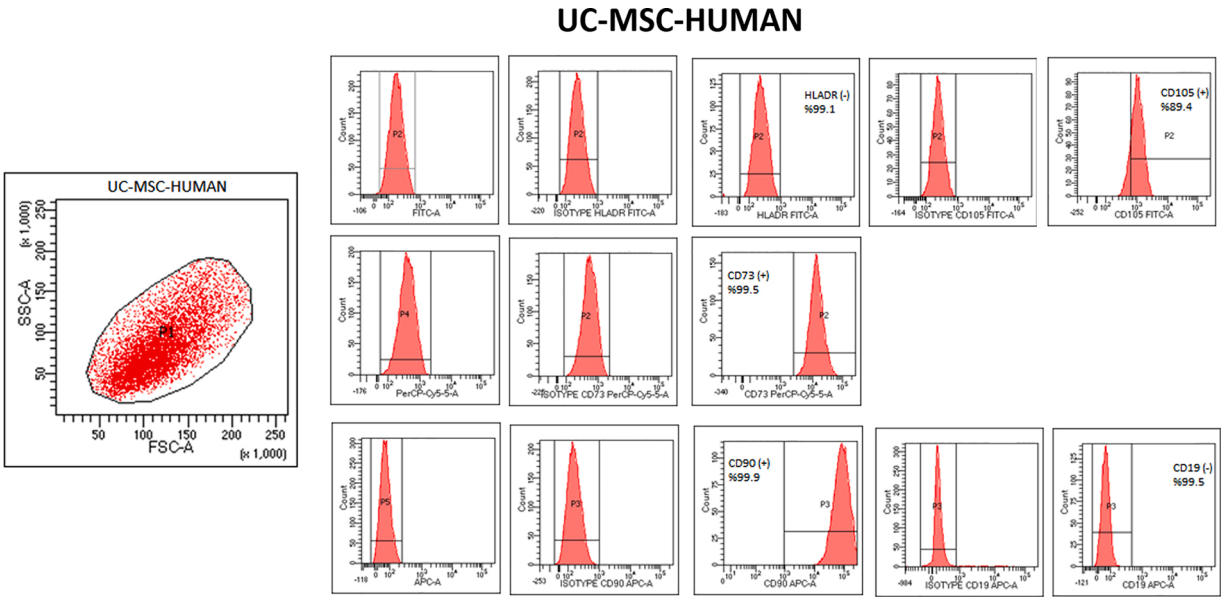

Fig. 3. Histogram plots of positive (CD 73, CD 90, CD 105) and negative (CD19 and HLA-DR) surface markers of MSCs in the flow cytometry device.

sciatic nerves were embedded in Cryomatrix (Thermo Fisher Scientific, Waltham, USA) were stored at -80 °C until sectioned with Cryotome device (Thermo Fisher Scientific, Waltham, USA). Sections taken at 7 μm thickness on special slides coated with poly L-lysine and stained with Oil Red O (Sigma Aldrich, O0625-100G, USA). Photographs were taken from these stained slides with photomicroscope (Olympus BX51; Olympus, Tokyo, Japan) and was done histopathological evaluation. Further, axon diameter measurement and axon counting carried out using the Image J Software 1.45 s. The diameter measurement of axons was done from randomly selected slides and in equal numbers to represent 1000 axons for each group. The number of axons was determined by counting from 20 different areas randomly selected for each group (Erken et al., 2014). All obtained data were analyzed statistically. For immunohistochemical analyze, slides were stained with NF-H (1/1000 dilution, NB300-135, Novus Biologicals, USA), NGF (1/300 dilution, ab6199, Abcam, UK), and cleaved caspase-3 (1/200 dilution, Cell Signaling Technology, 9661S, USA) antibodies using the indirect immunohistochemical method and accordance with the manufacturer's instructions. Secondary antibody (gtxRb IgG (H + L) Rhodamine, Millipore) was applied at 1/200 dilution. Photographs taken from immunohistochemically stained slides under photomicroscope. Immunoreactivity intensity measurement was performed using Image J Software. To evaluate caspase-3, caspase-3 positive cells counted. All immunohistochemical measurements were evaluated in randomly selected 10 different areas for each rat and each antibody.

2.7. Demonstration of PKH26-labeled MSCs in the sciatic nerve

To investigate the presence of PKH26-labeled cells in the sciatic nerve, part of the nerve was frozen directly in the cryomatrix, and stored at -80 °C. Then the sections of tissue were fixed with acetone, washed with PBS, and mounted with DAPI containing medium to visualize nucleus. After covering with coverslips, labeled cells were displayed under an immunofluorescence microscope.

2.8. Statistical analysis

Whether obtained data showed normal distribution or not was examined with the Kolmogorov-Smirnov normality test and the homogeneity of the variances with the Levene homogeneity test. Statistical analyzes were made using SPSS (SPSS for Windows version 13) package program. Comparisons between groups; One-Way Variance Analysis was used to calculate SFI measurements showing normal distribution. In case of a difference, multiple comparisons were made with the Tukey test. Kruskal-Wallis analysis was used for comparisons between groups in other variables that did not show normal distribution. When there was a difference, the Mann Whitney *U* test for multiple comparisons was done. $p < 0.05$ value was considered statistically significant.

3. Results

3.1. Characterization of MSCs

The plastic adherent, spindle-shaped cells appeared around the small pieces of Wharton's jelly tissues 4 days after the primary culture and reached 70 % confluence on day 10.

According to the results of flow cytometry, the cells were positive for CD105 (89.4 %), CD73 (99.5 %) and CD90 (99.9 %) and negative for

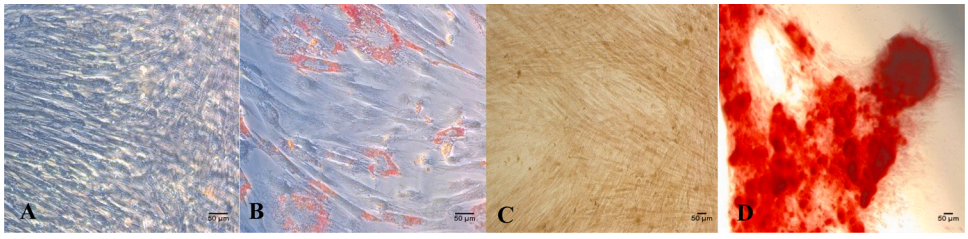

Fig. 4. Microscopic images of differantiation of MSC on 21 st day. It was shown that adipogenic (**A:** Control, **B:** Adipogenic transformation, 20x) and osteogenic (**C:** Control, **D:** Osteogenic transformation, 10x) transformation was performed by applying differentiation media to MSCs for 21 days. In the cells undergoing adipogenic transformation **(B)** Oil O red-stained oil droplets in the cytoplasm were colored red. In osteogenic transformation **(D)**, it was observed that calcium deposits stained red with Alizarin red stainings (scale bar; 50 μm).

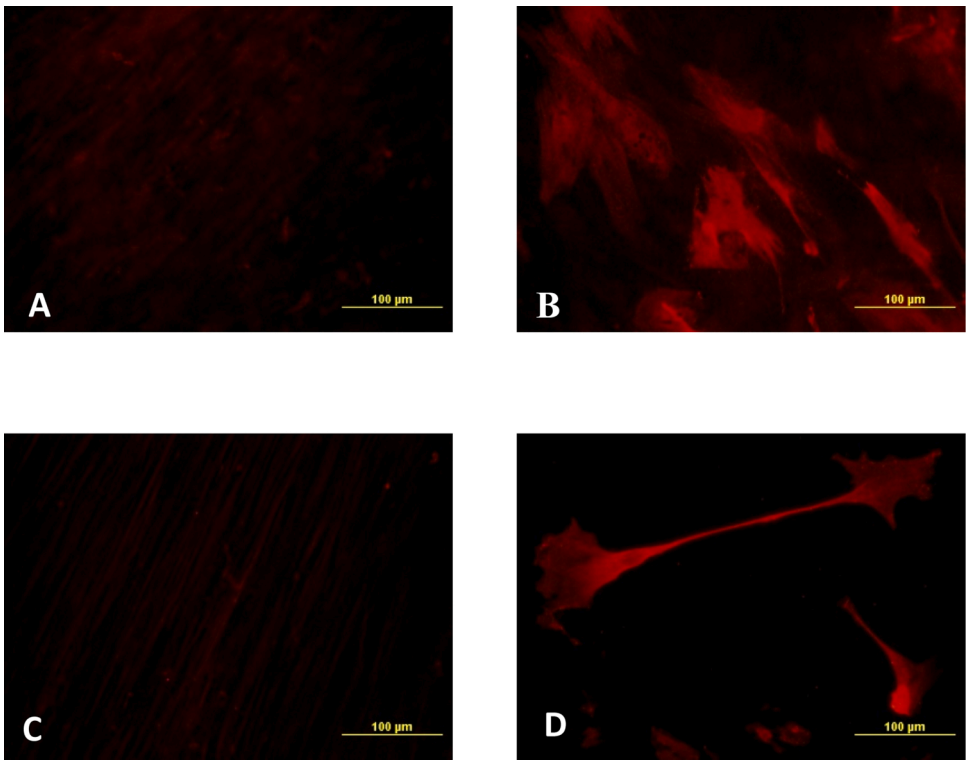

Fig. 5. Fluorescencent images verify multipotency of MSCs. MSCs were treated with growth medium **(A,C)**, adipogenic differentiation media **(B),** osteogenic differentiation media **(D)** and then stained with anti-FABP4 (adipocyte marker, red) and anti-osteocalcin (osteocyte marker, red) antibodies (40x, scale bar; 100 µm).

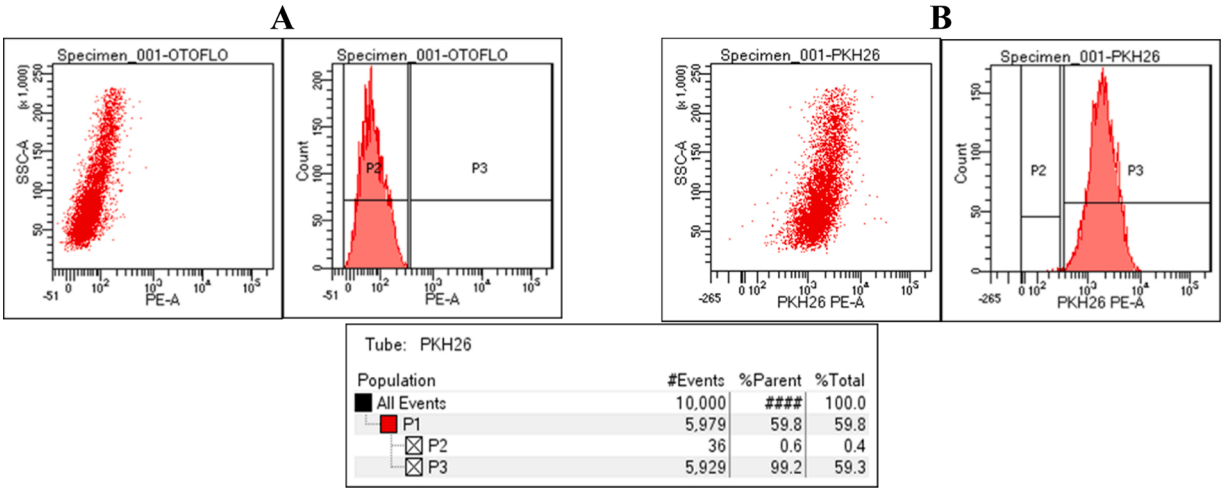

Fig. 6. Radiation of MSCs stained with PKH 26 in flow cytometry**. A:** Histograms of unstained cells. **B:**Histograms of stained cells. 99.2 % of the cells were stained with PKH26 in flow cytometry. There was a very small amount of radiation, 0.6 %, according to the histogram result of the cells that were not stained.

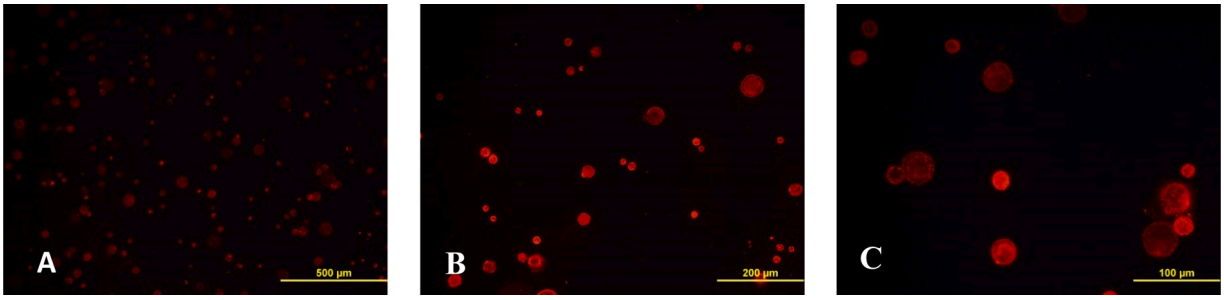

Fig. 7. Fluorescence microscope images of MSCs stained with PKH26. **A:**10x (scale bar; 500 µm) **B:**20x (scale bar; 200 µm) **C:**40 × . (scale bar; 100 µm).

Table 1
Sciatic functional index test statistics.

	Sham	CI	CI + EPO	CI + MSC	CI + EPO + MSC	p
0. day	−9,718 ± 144[a]	−8,601 ± 146[a]	−9,359 ± 197[a]	−9,315 ± 156[a]	−1,0178 ± 269[a]	0.464
14. day	−10,020 ± 433[a]	−64,211 ± 1816[b]	−48,441 ± 669[bc]	−48,383 ± 1076[bc]	−47,465 ± 1549[c]	0.001
28. day	−9,712 ± 226[ac]	−28,943 ± 507[b]	−27,231 ± 804[b]	−20,921 ± 833[bc]	−18,073 ± 924[c]	0.001

Data are expressed as mean ± standard deviation. The same letters in the same line indicate the similarity between the groups and the different letters indicate the difference between the groups.

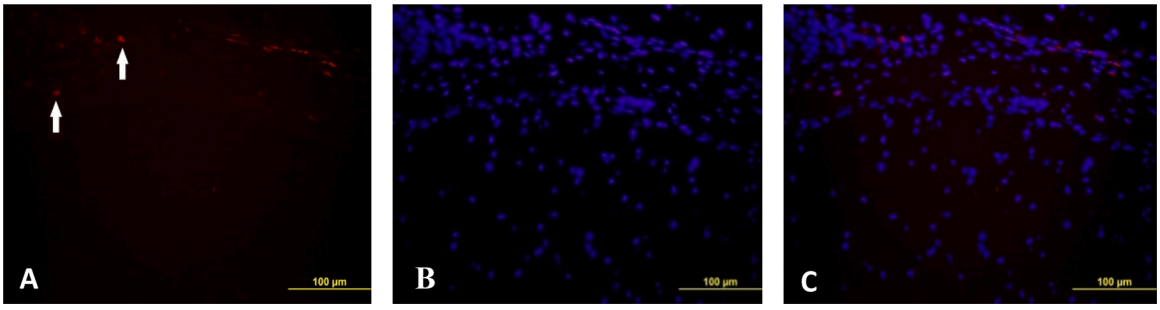

Fig. 8. A: PKH26 **B:** DAPI **C:** Merge of PKH26 and DAPI. (White arrow: PKH26-positive MSCs, 40x) (scale bar; 100 µm).

HLA-DR (0.9 %) and CD19 (0.5 %), indicating that the cells are MSCs (Fig. 3).

Additionally, the differentiation potential of MSCs toward the adipogenic and osteogenic lineages was tested with immunohistochemical and immunofluorescence stainings. Red stained lipid droplets were observed in the cytoplasm of cells cultured in adipogenic induction medium, while red stained calcium deposits were observed in cells maintained in osteogenic induction medium. No lipid droplets or calcium deposits formation were observed in MSCs maintained in growth medium (Fig. 4). In addition, immunofluorescence analysis showed similar results. Undifferentiated MSCs were negative for both FABP4 and osteocalcin, whereas MSCs in adipogenic and osteogenic-induction media were positive for FABP4 and osteocalcin, respectively (Fig. 5).

3.2. PKH26 labeling efficacy of MSCs

The flow cytometry analysis of labeled MSCs showed that the labeling efficacy of cells was 99.2 % (Fig. 6). The rate of viable cells counted on the Thoma cell counting chamber after PKH26 staining was 96.8 % (data not shown). PKH26 stained cells showed red fluorescent images under fluorescence microscopy (Fig. 7).

3.3. SFI assessment

There was no significant difference between groups in SFI test on 0th day ($p > 0.05$). After injury on the 14th day; SFI values in the injured groups were significantly lower than in the Sham group ($p < 0.05$). The SFI value of the CI + EPO + MSC group was significantly higher than the CI group ($p < 0.05$). After injury on the 28th day; SFI values in the injured groups were still lower than in the Sham group. The SFI value of the CI + EPO + MSC group was significantly higher than the CI group ($p > 0.05$). Moreover, there was no statistically significant difference between the CI + EPO + MSC and Sham group ($p > 0.05$) (Table 1).

3.4. Presence of PKH26-labeled MSCs in the sciatic nerve

The observation of a few red labeled cells in almost every area of the tissue suggests that the homing of cells in damaged tissue (Fig. 8).

3.5. Light microscopic findings

Epineurium, perineurium, nerve fascicles, and axonal organization were regular in the Sham group. The axon shapes were round in cross-section and myelin sheath surrounding the axon stained red with Oil Red O. Degenerative changes in the CI group were most pronounced compared to other experimental groups. The nerve fascicles of the CI group were quite irregular. There were also gaps between and inside fascicles. Although it was clearly observed that the axons of the CI group were not stained with Oil Red O, hemorrhagic and necrotic areas were not observed (Fig. 9D). Regeneration was observed in all treatment groups, but this regeneration was poor in the CI + EPO group, while a better recovery was found in the CI + MSC group. In the CI + MSC group, axonal organization was quite regular. In addition, when the CI + MSC group compared to all treatment groups, it was determined that the myelin sheaths were thicker and more stained with Oil Red O. When all experimental groups compared with each other regarding histopathological features, the fascicles and perineurium of the peripheral nerves were preserved in all rats, except for the CI group. Histopathologically, CI + MSC group was closest to the Sham group (Fig. 9).

When the experimental groups were compared in terms of axon number, the number of axon in the CI group was lower than the Sham group, and this result was statistically significant ($p < 0.05$). The number of axons was significantly higher in CI + MSC and CI + EPO + MSC groups compared to CI group ($p < 0.05$). The number of axons in the CI + MSC group was also significantly higher than in the CI + EPO group ($p < 0.05$) (Table 2). When the groups were assesed in terms of axon diameter, it was determined that the diameter of axon was significantly lower in the CI, CI + MSC and CI + EPO + MSC groups compared to the Sham group ($p < 0.05$). However, the axon diameter in the treatment groups was significantly higher than in the CI group ($p < 0.05$). The axon diameter in the CI + EPO and CI + EPO + MSC groups was significantly higher than in the CI + MSC group ($p < 0.05$), (Table 2).

3.6. Immunofluorescent findings

Immunofluorescent findings Sections obtained from sciatic nerve tissues were stained with NF-H (Fig. 10). According to the data acquired from the NF-H staining measurements, the NF-H intensity in the Fig. 10 - CI group was significantly lower than in the Sham group ($p < 0.05$). The intensity of NF-H in all treatment groups was significantly higher than the Fig. 10 - CI group ($p < 0.05$). It was concluded that one of the treatment groups Fig. 10 - CI + MSC group was the highest NF-H intensity (Table 3).

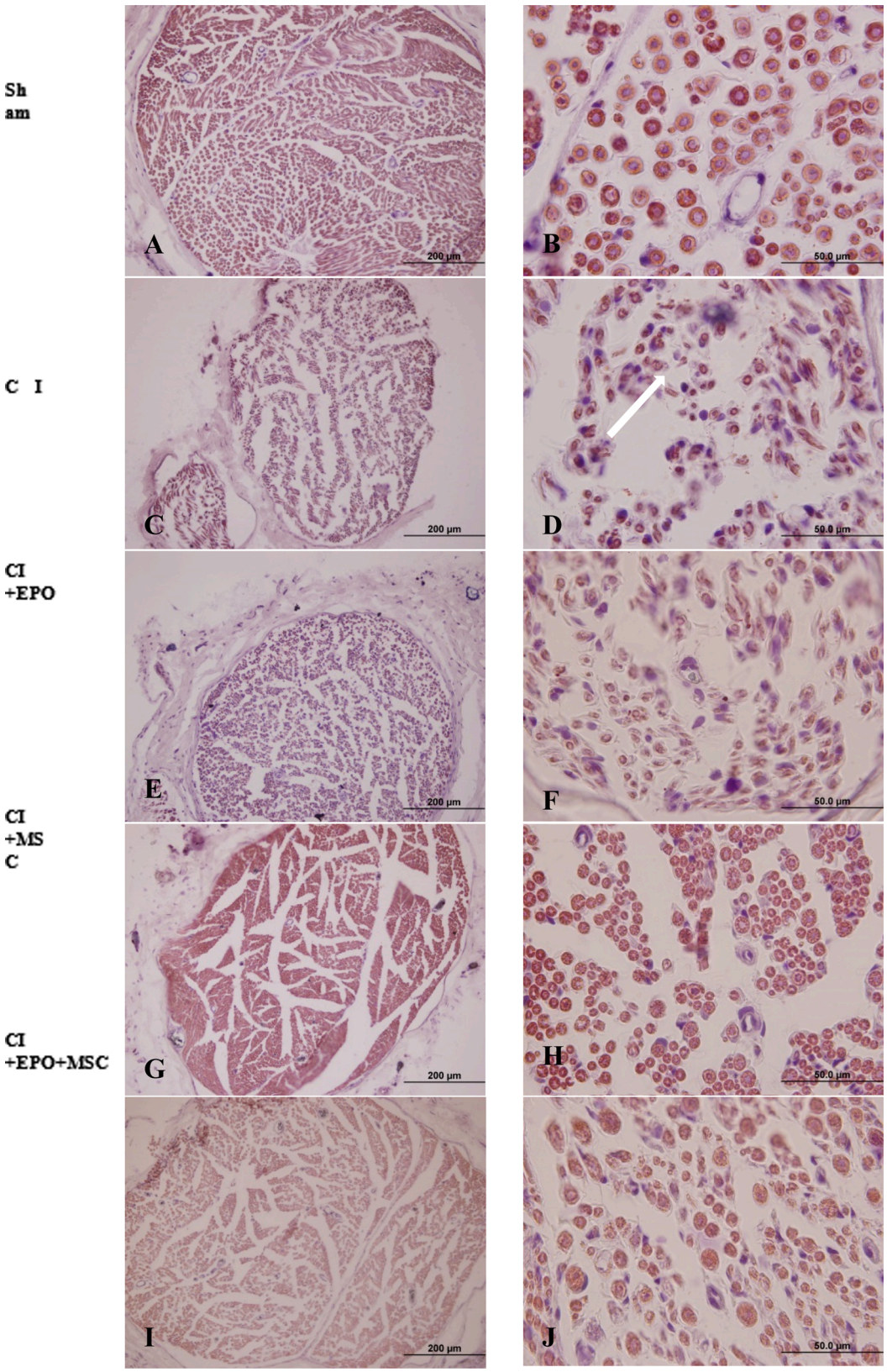

Fig. 9. Images of groups with Oil Red O stainings (white arrow: degeneration). In the Sham group, nerve fascicles, myelin sheaths and axonal organization appear regular and uniform **(A,B)**. Nerve fascicles of the CI group were quite irregular and also were gaps between and inside fascicles **(C,D)**. In the CI + EPO group, myelin regeneration appears poor, but myelin thickness was greater and axonal organization was more regular compared to the CI group **(E,F)**. Although the group with the best regeneration was CI + MSC **(G,H)**, there were good axonal organization and regeneration in the CI + EPO + MSC group **(I,J)**. (A,C,E,G,I: 40x, scale bar; 100 µm) (B,D,F,H,J: 100x, scale bar; 50 µm).

Table 2
Statistics table of axon diameter and number in sciatic nerve stained with oil red O.

	Sham	CI	CI + EPO	CI + MSC	CI + EPO + MSC	p
Axon Number	30,550 (260,00−350,75)[ac]	18,350 (131,75−245,75)[b]	25,000 (215,75−279,75)[ab]	31,700 (286,50−341,00)[c]	28,900 (258,25−351,75)[ac]	0.001
Axon Diameter	144,166 (132,22−154,41)[a]	109,553 (96,80−123,80)[b]	147,020 (134,51−159,15)[a]	126,443 (117,44−136,70)[c]	136,855 (129,03−147,16)[d]	0.001

The data are expressed in the median (1 st quarter-3rd quarter). The same letters in the same line represent the similarity between the groups and the different letters represent the difference between the groups.

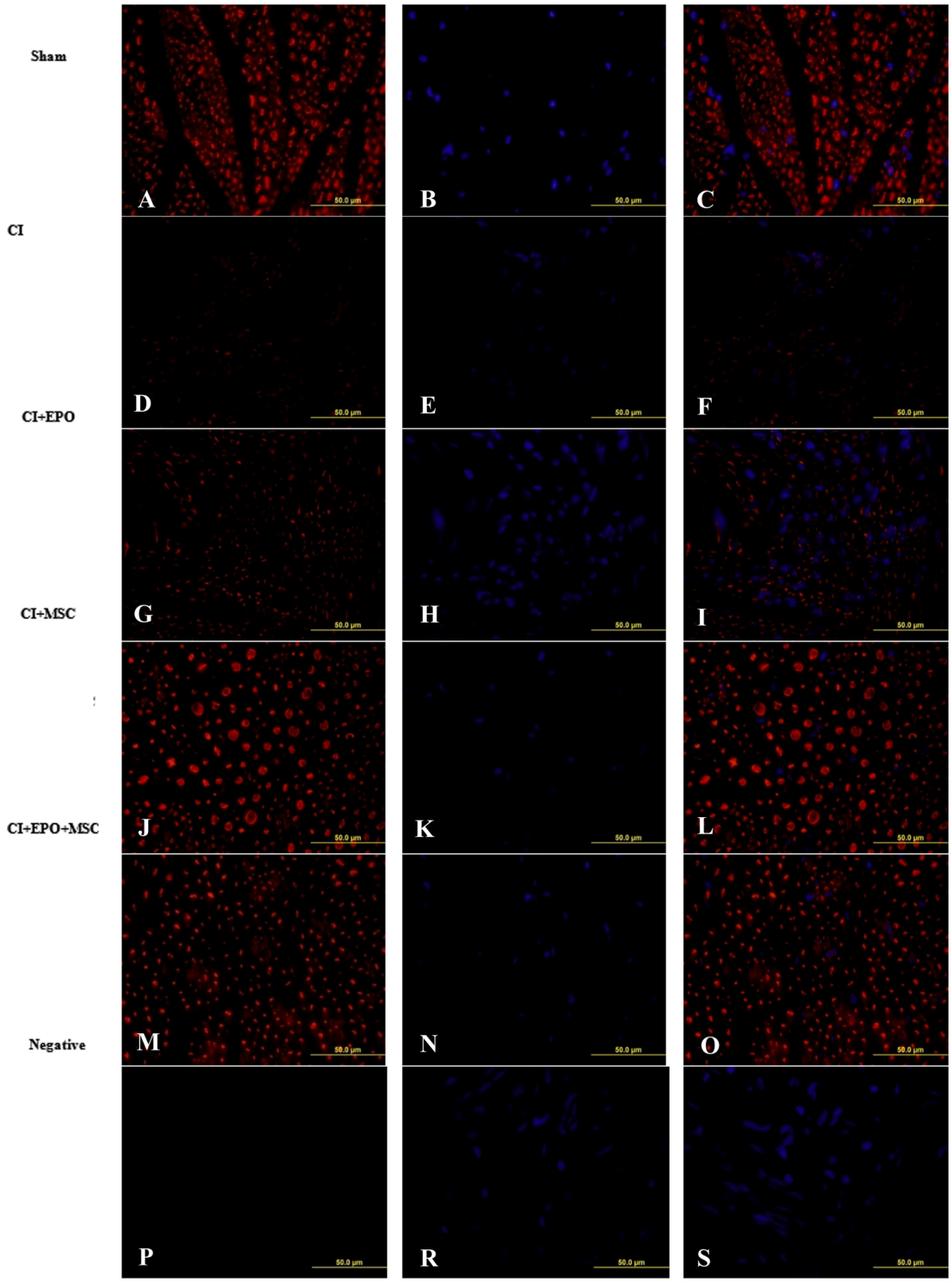

Fig. 10. Immunofluorescence staining of NF-H. Red staining indicates fluorescence coloration of secondary antibodies. Black area indicates background. It was seen that the intensity of NF-H is the highest in the Sham group **(A,B,C)**. Groups treated with MSCs and EPO exhibited higher intensity of NF-H than the CI group. Among the treatment groups, the group with the highest intensity of NF-H was the CI + MSC group **(J, K, L)**. (100x, scale bar; 50 µm).

Table 3
Immunoreactivity assessment statistics.

	Sham	CI	CI + EPO	CI + MSC	CI + EPO + MSC	p
NF	12,818,000 (9854–16153,25)[a]	2,655,500 (1761,25–4036,25)[b]	4,301,000 (2622,00–6792,00)[c]	9,620,000 (6218,50–13272,50)[d]	6,836,000 (4809,50–10299,50)[e]	0.001
NGF	13,891 (10,77–15,83)[a]	25,665 (20,67–30,60)[b]	22,800 (18,37–28,23)[b]	18,598 (14,82–25,74)[c]	23,065 (15,72–31,19)[b]	0.001
Caspase-3	0,0(0,0–0,0)[a]	0,0(0,0–0,0)[a]	0,0(0,0–0,0)[a]	0,0(0,0–0,0)[a]	0,0(0,0–0,0)[a]	0.382

The data are expressed in the median (1 st quarter-3rd quarter). The same letters in the same line indicate the similarity between the groups and the different letters indicate the difference between the groups.

We performed immunofluorescence staining to evaluate the intensity of NGF immunoreactivity (Fig. 11). NGF immunreactivity intensity in the injured groups was significantly higher than the Sham group ($p < 0.05$). When the Fig. 11 - CI group and treatment groups were compared, NGF intensity was significantly lower only in the Fig. 11 - CI + MSC group ($p < 0.05$). NGF intensity in the Fig. 11 - CI + MSC group was significantly lower than the Fig. 11 - CI + EPO and Fig. 11 - CI + EPO + MSC groups ($p < 0.05$), (Table 3). To demonstrate apoptosis in the sciatic nerve, apoptotic cell marking was performed with caspase-3 immunofluorescence staining (Fig. 12). There were no significant differences between the number of apoptotic cells in all experimental groups ($p > 0.05$) (Table 3).

4. Discussion

In this study, we aimed to investigate the effects of UCS-MSC and EPO on the repair of peripheral nerve damage in a rat crushed sciatic nerve model. In this regard, successfully isolated from human umbilical cord stroma the cells was labeled with PKH26 and made ready for use for the experiment. After the crush injury was surgically created, treatments were applied according to the groups. We performed SFI tests to evaluate the physiological recovery of rats and also stained Oil Red O to show histopathological analysis and evaluate the number and the diameter of axons. Immunoreactivity of nerve growth factor, neurofilament-H and caspase-3 were determined by immunofluorescence staining in nerve tissue.

MSCs should at least express some of MSC markers including CD105, CD90, and CD73 and lack the expression of a few hematopoietic cell markers such as CD11b, CD79a, CD19, and human leukocyte antigen-DR isotype (HLA-DR) (Dominici et al., 2006). In our study, successful isolation of MSCs from human umbilical cord stroma has been confirmed by analysis of these markers. Additionally, when we look at the studies on MSCs; we see that only the expression of some CD markers (Hankamolsiri et al., 2016; Pham et al., 2018; Shu et al., 2018) and adipogenic and osteogenic differentiations of cells (Hankamolsiri et al., 2016) has been analyzed as we did.

It is difficult to ensure regeneration of peripheral nerve injuries fully with current treatment methods. Although it is technically possible to reconstruct nerves at fascicular level by surgical repair, it is not feasible at the axonal level. There have been many studies using different surgical repairs, drugs, hormones or biological products to improve nerve healing (Grinsell and Keating, 2014; Hu et al., 2007; Noorafshan et al., 2011; Sundem et al., 2016). Due to these deficiencies in primary surgical repair, in addition to surgery, stem cell treatments have been applied. Previous studies have been reported that MSCs is useful utility for sciatic nerve regeneration (Fernandes et al., 2018; Gärtner et al., 2012).

The way of administration in different studies varies as local or systemic route. Although MSCs were delivered with chitosan-coated tubules (Li et al., 2018), allogenic nerve grafts (Hu et al., 2007), venous grafts (Eren et al., 2018) and within the matrigel (Fernandes et al., 2018) in a number of studies, some others have applied locally (Ma et al., 2017), as we did. Use of autogenic venous graft will create an additional inflammatory site in body and increase risk of infection. When it comes to use of allogeneic and xenogenic grafts, there are challenges such as risk of rejection and need for a professional team requiring microsurgery to manage process. Considering these, in our study, we applied stem cells and locally to the injured nerve.

Stem cell sources used for nerve regeneration vary in the literature. The UCS-MSC are more effective than other MSCs types in terms of their apoptosis-inhibiting and tumor suppressing properties. As they are hypoimmunogenic, they do not usually cause rejection in autologous and allogenic transplantation. At the same time, its features such as being easy to obtain and free from ethical limitations were our main reasons for preference (Karahuseyinoglu et al., 2007). EPO's effect on neuroregeneration has also been shown in previous studies (Geary et al., 2017; Sekiguchi et al., 2003; Çelik et al., 2002). However, most of the methods and materials used in these studies have not taken part in clinical practice yet.

In peripheral nervous system, EPO improves nerve regeneration by inhibiting apoptosis, and protecting against oxidative damage. After injury, EPO stimulates axonal growth with its effects on Schwann cells, and contributes to angiogenesis. (Byts and Sirén, 2009). It has been reported that EPO treatment enhance migration of MSCs to injury site (Liu et al., 2013). In this study, we tested the hypothesis that EPO and MSCs will have a synergistic effect by increasing the effectiveness of MSCs in addition to their regenerative effects. Although we did not observe in histopathological analyzes and immunohistochemistry result, we observed this synergistic effect in the SFI test.

In the literature, clamp form and determined duration of pressure applied by clamp used in crush injury models of sciatic nerve varies (Akın et al., 1997; Beer et al., 2001; Mullerad et al., 2006). Also, in these studies, due to different clamp types, constant pressure for each rat is not at the same level since some of clamps do not apply constant pressure. In our study, we determined the duration of pressure as 90 s and preferred to use bulldog clamp that applies constant pressure in sciatic nerve.

SFI test is an important physiological test that measures regaining of motor, sensory and proprioceptive function, which is frequently used to evaluate sciatic nerve regeneration (Luis et al., 2007). In a study, a positive correlation was found between fiber diameter, myelin thickness, axon diameter and SFI test results (Martins et al., 2006). In our study, there was a significant increase in axon diameter in the CI + EPO, CI + MSC and CI + EPO + MSC groups compared to CI group. In rats given EPO, axon diameter increase was higher than CI + MSC. However, in CI + EPO and CI + EPO + MSC groups, we observed that recovery was slower compared to the CI + MSC group despite regeneration observed in these EPO treated groups. Because of that myelin sheath thickness determines diameter of an axon and myelin layer of newly regenerated nerve fibers are thicker (Kierszenbaum, 2015), we can attribute this diameter increase in the groups given EPO to being in early phases of regeneration. Because the myelin sheath thickness determines the diameter of the axon. The myelin layer of new fibers is thicker. Studies have shown that rhEPO can be effective in the treatment of neuropathic pain after peripheral nerve injury (Campana and Myers, 2003). In this vein, although regeneration evaluated histopathologically was better and statistically significant in the CI + MSC group, it showed that the SFI test results in the CI + EPO + MSC group were better than the CI + MSC group due to fact that EPO may be associated with reducing neuropathic pain.

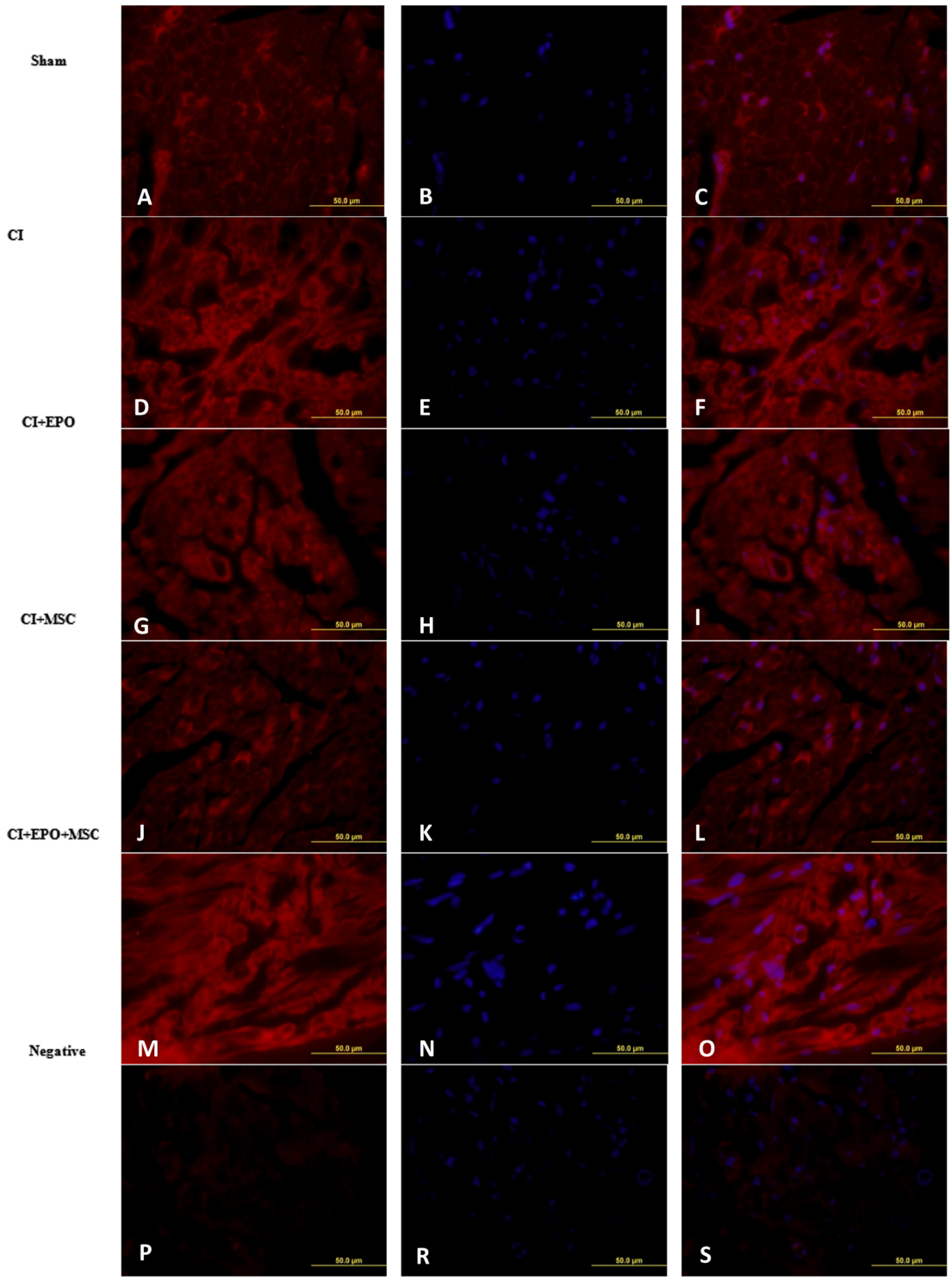

Fig. 11. Immunofluorescence staining of NGF. Red staining indicates fluorescence coloration of secondary antibodies. Black area indicates background. It was seen that the intensity of NGF is the highest in the CI group **(D,E,F)**. Groups treated with MSCs and EPO had lower intensity of NGF than the CI group. Among the treatment groups, the group with the lowest intensity of NGF was the CI + MSC group **(J, K, L)**. (100x, scale bar; 50 µm).

In another study; on the 14th and 21 st days after the injury, the SFI test showed a significant improvement in MSC group and on the 35th day, experimental animals in injury and MSC groups regain almost entirely motor functions (Marconi et al., 2012). In our study, on the 14th day after injury, SFI values of groups that we made injury were significantly lower than the Sham group. SFI value of CI + EPO + MSC group were higher significantly compared to CI group. This showed us that the best functional recovery on the 14th day was in CI + EPO + MSC group, and this improvement was statistically significant compared to CI group. Regarding SFI test performed on 28th day, when Sham group and other experimental groups were compared with each other, SFI values were still low in all injured groups, while values of CI + EPO + MSC group was significantly higher than CI group. Moreover, this SFI value of CI + EPO + MSC group was quite similar to value obtained from Sham group.

Neurofilaments, component of neural cytoskeleton, have been shown

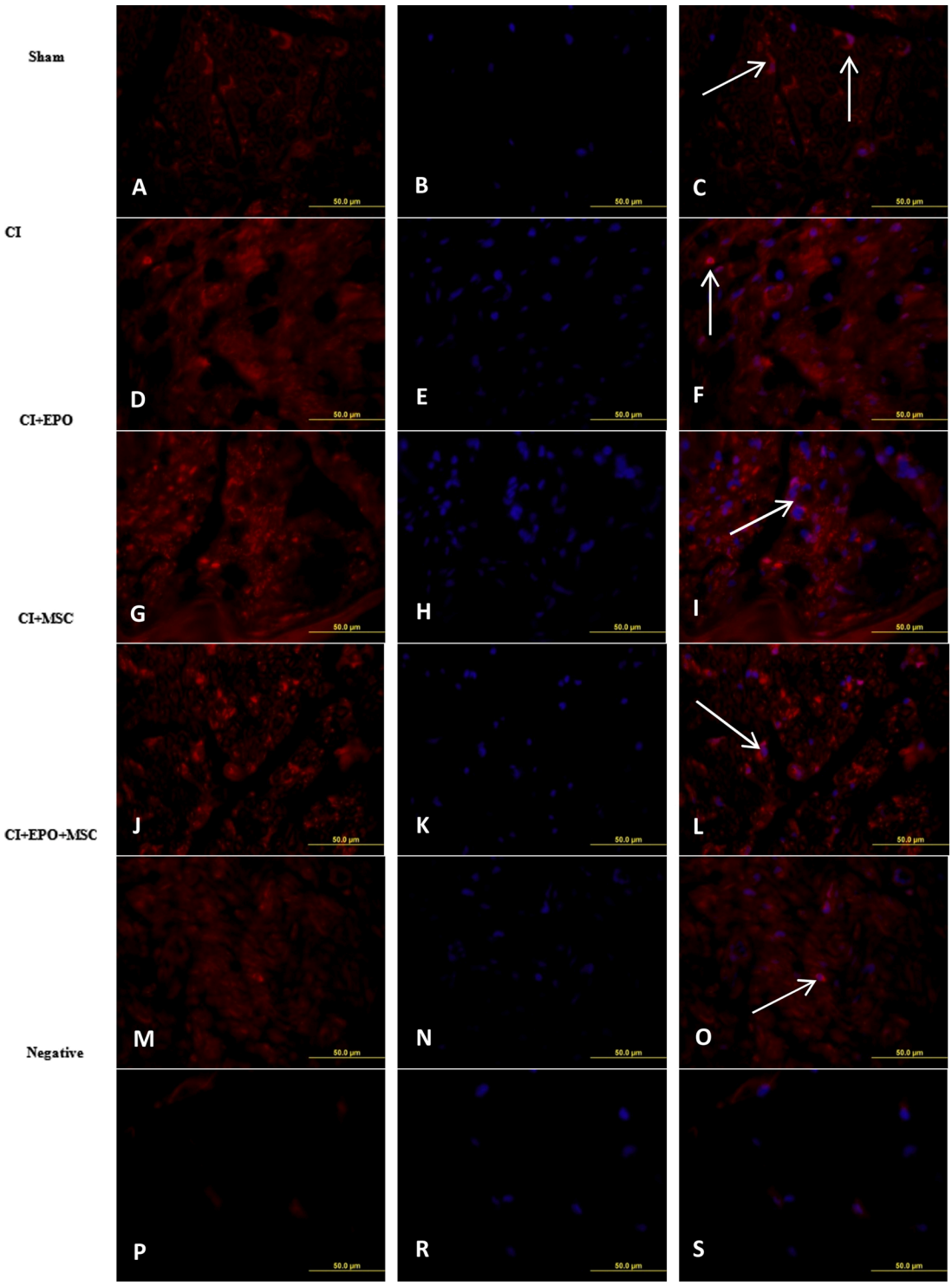

Fig. 12. Immunofluorescence staining of Caspase-3 (Thin white arrow: caspase-3 immunoreactivity-positive cell). Red staining indicates fluorescence coloration of secondary antibodies. Black area indicates background. Caspase-3-positive cells were seen in each group, but there was no significantly difference between the groups. (100x, scale bar; 50 µm).

to be impaired in many neurodegenerative diseases (Liua et al., 2004). The emergence of phosphorylated NF-H is acknowledged as a marker of mature neurons (Sanna et al., 2017). The NF-H levels were compared between the groups in a study, where injury established by complete sciatic nerve transection. According to the results they obtained, NF-H levels were significantly lower in injury group compared to treatment groups (Eren et al., 2018). In our study, we determined that the NF-H intensity in CI group was significantly lower than other all groups. While the highest NF-H density observed in Sham group; we found that, among treated groups, the NF-H intensity in CI + MSC group was most similar to Sham group. In addition, the intensity in CI + EPO and CI + EPO + MSC groups also higher significantly compared to CI group.

A neurotrophic factor, NGF, is synthesized from macrophage, Schwann cells and fibroblasts after nerve injury. It was found that NGF reduces cell death of damaged neurons, affects the direction of axonal bud growing, increases the number of myelinated axons and myelin

thickness, improves neural internal organization and accelerates nerve regeneration (Zhuk and Kalyunov, 1997). In a CI study, 4 weeks after injury, the control and Sham groups show similar NGF levels and also lowest among groups. In CI group and treatment groups, NGF levels were shown to be higher and significant compared to non-injured groups (Dias et al., 2019). The results of NGF immunoreactivity in our study were consistent with those of Dias Fj et al. In our study, the lowest NGF immunoreactivity was determined in Sham group, while NGF level was highest in CI group. NGF level in CI + MSC group was significantly lower compared to CI, CI + EPO, CI + EPO + MSC groups. The NGF level in the CI + MSC group show the most similar results to Sham group. We interpreted that the level of NGF secreted in response to injury was the lowest in the CI + MSC group, so it can be thought that this group presents later stage properties of regeneration at the end of the 4th week.

Apoptosis in Schwann cells occurs by expressing caspase-3 within a few hours following traumatic injury and this expression is a good indicator for Wallerian degeneration (Maeno et al., 2000; Stenberg et al., 2012). In a mice CI model, caspase-3 immunoreactivity examined and has been found that three days after nerve injury, intense caspase-3 immunoreactivity was found in whole endoneurium of sciatic nerves of wild-type mice, mildly found in sem mice (p38α = gene region that plays a role in regeneration) (Kato et al., 2013). Apoptotic process is thought to occur in the early phase of nerve injury. It is known that myelin debris was removed 2 weeks after the injury, and at 3rd week, Schwann cells proliferated and started the healing process (Ross and Pawlina, 2010). According to fact that in early stages after injury, damaged nerve tissue exhibits high levels of caspase-3 immunoreactivity. Our caspase-3 results that statistically insignificant and low suggest the fact that damaged nerve tissue exhibit high levels of caspase-3 immunoreactivity in early stages after injury (Kato et al., 2013).

5. Conclusion

Based on these data; it can be thought that MSC and EPO administration have positive effects on peripheral nerve regeneration. In SFI test, the group with the best recovery on the 14th and 28th days was CI + EPO + MSC and it was statistically significant ($p < 0.05$). Histopathologically, the best group was the CI + MSC group. We concluded that in terms of axon diameter and number of axons CI + MSC group was the highest regenerative capacity as a group ($p < 0.05$). In terms of NF-H and NGF density, CI + MSC group shows also similarity to results of the axon diameter and axon number ($p < 0.05$).

We think that the reason for functional improvement in the CI + EPO + MSC group is better than the histopathological improvement is due to the effect of EPO reducing neuropathic pain. Thus, we concluded that, in addition to histopathological recovery, pain reduction can improve quality of life in daily life. In addition, we think that MSC and EPO will be useful in treatment of crush nerve injury that we frequently encounter in clinical practice. Overall, we think that stem cell therapies alone or in combination with other substances contribute to treatment of patients suffered from nerve injury.

6. Limitations

PKH 26 is not a reliable enough monitoring agent as it can be transferred into host cells. So, it can cause false positive results. The accuracy of this method can be confirmed by a second method (Lassailly et al., 2010; Progatzky et al., 2013).

Due to termination time of our study, we could not detect apoptosis significantly through caspase-3 staining performed on the 28th day. To evaluate apoptosis, more efficient results can be obtained by performing this evaluation in early stages after injury.

Further studies can be made to measure the effect of MSCs more objectively by using advanced methods to show whether MSCs are transformed into Schwann cells and the like.

Ethical statement

For this study, the approval of Erciyes University Animal Experts Local Ethics Committee was received on 14/02/2018 and numbered 18/030, and was supported by Erciyes University Scientific Research Projects Unit with the project code numbered TTU-2018−8163. Ethical committee approval was obtained from the Erciyes University Clinical Research Ethics Committee with the decision of 2018/182 for the provision of the umbilical cord.

Funding

This work was supported by the Scientific Research Project Coordination Unit of Erciyes University (Project number: TTU-2018-8163).

Declaration of Competing Interest

No potential conflict of interest was reported by the authors.

Acknowledgments

We thank Erciyes University Scientific Research Projects Coordination for funding and the Faculty of Medicine, Department of Histology and Embryology (Kayseri / TURKEY) for their support.

References

Akın, O., Kutlay, M., Demirel, D., Kıbıcı, K., Elbüken, E., 1997. Effects of hyperbaric oxygen treatment on histopathological changes which developed in the acute stage rabbit sciatic nerve crush injury. Med. J. Ataturk Univ. 29, 500–506.

Arcasoy, M.O., 2008. The non-haematopoietic biological effects of erythropoietin. Br. J. Haematol. 141, 14–31.

Bain, J.R., Mackinnon, S.E., Hunter, D.A., 1989. Functional evaluation of complete sciatic, peroneal, and posterior tibial nerve lesions in the rat. Plast. Reconstr. Surg. 83, 129–138.

Bauer, C., 1995. Erythropoietin–from gene structure to therapeutic applications. J. Perinat. Med. 23, 77–81.

Beer, G.M., Steurer, J., Meyer, V.E., 2001. Standardizing nerve crushes with a non-serrated clamp. J. Reconstr. Microsurg. 17, 531–534.

Byts, N., Sirén, A.L., 2009. Erythropoietin: a multimodal neuroprotective agent. Exp. Transl. Stroke Med. 21 (1), 4. https://doi.org/10.1186/2040-7378-1-4.

Campana, R.R., Myers, W.M., 2003. Exogenous erythropoietin protects against dorsal root ganglion apoptosis and pain following peripheral nevre injury. Eur. J. Neurosci. 18, 1497–1506.

Çelik, M., Gökmen, N., Erbayraktar, S., Akhisaroğlu, M., Konakcı, S., Ulukuş, C., Genc, S., Genc, K., Sagiroglu, E., Cerami, A., Brines, M., 2002. Erythropoietin prevents motor neuron apoptosis and neurologic disability in experimental spinal cord ischemic injury. Proc. Natl. Acad. Sci. U.S.A. 99, 19PMC122352.

Chalfoun, C.T., Wirth, G.A., Evans, G.R., 2006. Tissue engineered nerve constructs: where do we stand? J. Cell. Mol. Med. 10, 309–317.

Chen, C.J., Ou, Y.C., Liao, S.L., Chen, W.Y., Chen, S.Y., Wu, C.W., Wang, C.C., Wang, W. Y., Huang, Y.S., Hsu, S.H., 2007. Transplantation of bone marrow stromal cells for peripheral nerve repair. Exp. Neurol. 204, 443–453. https://doi.org/10.1016/j.expneurol.2006.12.004.

Dias, F.J., Fazan, V.P.S., Cury, D.P., de-Almeida, S.R.Y., Borie, E., Fuentes, R., Coutinho-Netto, J., Watanabe, I.S., 2019. Growth factors expression and ultrastructural morphology after application of low-level laser and natural latex protein on a sciatic nerve crush-type injury. PLoS One 9 (14), e0210211. https://doi.org/10.1371/journal.pone.0210211.

Dominici, M., Blanc, K.L., Mueller, I., Cortenbach, I.S., Marini, F.C., Krause, D.S., Deans, R.J., Keating, A., Prockop, D.J., Horwitz, E.M., 2006. Minimal criteria for defining multipotent mesenchymal stromal cells. International Society for Cellular Therapy position statement. Cytotherapy 8, 315–317.

Elfar, J.C., Jacobson, J.A., Puzas, J.E., Rosier, R.N., Zuscik, M.J., 2008. Erythropoietin accelerates functional recovery after peripheral nerve injury. J. Bone Joint Surg. Am. 90, 1644–1653.

El-Kordi, A., Radyushkin, K., Ehrenreich, H., 2009. Erythropoietin improves operant conditioning and stability of cognitive performance in mice. BMC Biol. 8 (7), 37.

Eren, A., Atalar, H., Seymen, C.M., Pınarlı, F.A., Kaplanoglu, G.T., Turanlı, S., 2018. Sutureless approach with vein grafts and mesenchymal stem cells in primary nerve repair: functional and immunohistological results. Microsurgery 38, 780–789.

Erken, H.A., Koc E.R.¸Yazıc, H.I., Yay, A., Önder, G.Ö., Sarıcı, S.F., 2014. Selenium partially prevents cisplatin-induced neurotoxicity: a preliminary study. NeuroToxicol. 42, 71–75.

Evans, G.R.D., 2001. Peripheral nerve injury: a review and approach to tissue engineered constructs. Anat. Rec. 263, 396–404.

Fernandes, M., Valente, S.G., Sabongi, R.G., Gomes Dos Santos, J.B., Leite, V.M., Ulrich, H., Nery, A.A., da-Silva Fernandes, M.J., 2018. Bone marrow-derived

mesenchymal stem cells versus adipose-derived mesenchymal stem cellsfor peripheral nerve regeneration. Neural Regen. Res. 13, 100–104.
Gärtner, A., Pereira, T., Alves, M.G., Armada-da-Silva, P.A., Amorim, I., Gomes, R., Ribeiro, J., França, M.L., Lopes, C., Carvalho, R.A., Socorro, S., Oliveira, P.F., Porto, B., Sousa, R., Bombaci, A., Ronchi, G., Fregnan, F., Varejão, A.S., Luís, A.L., Geuna, S., Maurício, A.C., 2012. Use of poly (DL-lactide-e-caprolactone) membranes and mesenchymal stem cell from the Wharton's jelly of the umbilical cord for promoting nerve regeneration in axonotmesis. Differentiation 84, 355–365. https://doi.org/10.1016/j.diff.2012.10.001.
Geary, M.B., Li, H., Zingman, A., Ketz, J., Zuscik, M., De-Mesy Bentley, K.L., Noble, M., Elfar, J.C., 2017. Erythropoietin accelerates functional recovery after moderate sciatic nerve crush injury. Muscle Nerve 56, 143–151.
Grinsell, D., Keating, G.P., 2014. Peripheral nerve reconstruction after injury: a review of clinical and experimental therapies. Biomed Res. Int., 698256
Haapaniemi, T., Nylander, G., Kanje, M., Dahlin, L., 1998. Hyperbaric oxygen treatment enhances regeneration of the rat sciatic nerve. Exp. Neurol. 149, 433–438.
Hankamolsiri, W., Manochantr, S., Tantrawatpan, C., Tantikanlayaporn, D., Tapanadechopone, P., Kheolamai, P., 2016. The effects of high glucose on adipogenic and osteogenic differentiation of gestational tissue-derived MSCs. Stem Cells Int. https://doi.org/10.1155/2016/9674614.
He, X.Z., Wang, W., Hu, T.M., Ma, J.J., Yu, C.Y., Gao, Y.F., Cheng, X.L., Wang, P., 2016. Peripheral nerve repair: theory and technology application. Zhongguo Zuzhi Gongcheng Yanjiu. 20, 1044–1050.
Hu, J., Zhu, Q.T., Liu, X.L., Xu, Y.B., Zhu, J.K., 2007. Repair of extended peripheral nerve lesions in rhesus monkeys using acellular allogenic nerve grafts implanted with autologous mesenchymal stem cells. Exp. Neurol. 204, 658–666.
Jessen, K.R., Mirsky, R., 2019. The success and failure of the schwann cell response to nerve injury. Front. Cell. Neurosci. 13, 33.
Karahuseyinoglu, S., Cinar, O., Kilic, E., Kara, F., Akay, G.G., Demiralp, D.O., Tukun, A., Uckan, D., Can, A., 2007. Biology of stem cells in human umbilical cord stroma: in situ and in vitro surveys. Stem Cells 25, 319–331. https://doi.org/10.1634/stemcells.2006-0286.
Kato, N., Matsumoto, M., Kogawa, M., Atkins, G.J., Findlay, D.M., Fujikawa, T., Oda, H., Ogata, M., 2013. Critical role of p38 MAPK for regeneration of the sciatic nerve following crush injury in vivo. J. Neuroinflammation 3 (10), 1.
Konishi, Y., Chui, D.H., Hirose, H., Kunishita, T., Tabira, T., 1993. Trophic effect of erythropoietin and other hematopoietic factorson central cholinergic neurons in vitro and in vivo. Brain Res. 609, 29–35.
Lassailly, F., Griessinger, E., Bonnet, D., 2010. Microenvironmental contaminations" induced by fluorescent lipophilic dyes used for noninvasive in vitro and in vivo cell tracking. Blood 115, 5347–5354.
Lavasani, M., Thompson, S.D., Pollett, J.B., Usas, A., Lu, A., Stolz, D.B., Clark, K.A., Sun, B., Péault, B., Huard, J., 2014. Human muscle-derived stem/progenitor cells promote functional murine peripheral nerve regeneration. J. Clin. Invest. 124, 1745–1756.
Li, R., Liu, Z., Pan, Y., Chen, L., Zhang, Z., Lu, L., 2013. Peripheral nerve injuries treatment: a systematic review. Cell Biochem. Biophys. 68, 449–454.
Li, R., Liu, H., Huang, H., Bi, W., Yan, R., Tan, X., Wen, W., Wang, C., Song, W., Zhang, Y., Zhang, F., Hu, M., 2018. Chitosan conduit combined with hyaluronic acid prevent sciatic nerve scar in a rat model of peripheral nerve crush injury. Mol. Med. Rep. 17, 4360–4368.
Liu, N., Tian, J., Cheng, J., Zhang, J., 2013. Effect of erythropoietin on the migration of bone marrow-derived mesenchymal stem cells to the acute kidney injury microenvironment. Exp. Cell Res. 1 (319), 2019–2027.
Liua, Q., Xie, F., Siedlak, S.L., Nunomurac, A., Hondaa, K., Moreira, K.I., Zhua, X., Smith, M.A., Perry, G., 2004. Neurofilament proteins in neurodegenerative diseases. Cell. Mol. Life Sci. 61, 3057–3075. https://doi.org/10.1007/s00018-004-4268-8.
Luis, A.L., Amado, S., Geuna, S., Rodrigues, J.M., Simões, M.J., Santos, J.D., Fregnan, F., Raimondo, S., Veloso, A.P., Ferreira, A.J., Armada-da-Silva, P.A., Varejão, A.S., Maurício, A.C., 2007. Long-term functional and morphological assessment of a standardized rat sciatic nerve crush injury with a non-serrated clamp. J. Neurosci. Methods 163, 92–104.
Ma, Y., Ge, S., Zhang, J., Zhou, D., Li, L., Wang, X., Su, J., 2017. Mesenchymal stem cell-derived extracellular vesicles promote nerve regeneration after sciatic nerve crush injury in rats. Int. J. Clin. Exp. Pathol. 1 (10), 10032–10039.
Maeno, I., Ishizaki, Y., Kanaseki, T., Hazama, A., Okada, Y., 2000. Normotonic cell shrinkage because of disordered volume regulation is an early prerequisite to apoptosis. Proc. Natl. Acad. Sci. U. S. A. 15 (97), 9487–9492.
Marconi, S., Castiglione, G., Turano, E., Bissolotti, G., Angiari, S., Farinazzo, A., Constantin, G., Bedogni, G., Bedogni, A., Bonetti, B., 2012. Human adipose-derived mesenchymal stem cells systemically injected promote peripheral nerve regeneration in the mouse model of sciatic crush. Tissue Eng. Part A 18, 1264–1272.
Martins, R.S., Siqueira, M.G., da Silva, C.F., Plese, J.P., 2006. Correlation between parameters of electrophysiological, histomorphometric and sciatic functional index evaluations after rat sciatic nerve repair. Arq. Neuropsiquiatr. 64, 750–756.
Morishita, E., Masuda, S., Nagao, M., Yasuda, Y., Sasaki, R., 1997. Erythropoietin receptor is expressed in rat hippocampal and cerebral cortical neurons, and erythropoietin prevents in vitro glutamate-induced neuronal death. Neuroscience 76, 105–116.
Mullerad, M., Donohue, J.F., Li, P.S., Scardino, P.T., Mulhall, J.P., 2006. Functional sequelae of cavernous nerve injury in the rat: is there model dependency. J. Sex. Med. 3, 77–83.
Noorafshan, A., Omidi, A., Karbalay-Doust, S., 2011. Curcumin protects the dorsal root ganglion and sciatic nerve after crush in rat. Pathol. - Res. Pract. 15 (207), 577–582.
Ozmen, S., Ayhan, S., Latifoglu, O., Siemionow, M., 2002. Stamp and paper method: a superior technique for the walking track analysis. Plast. Reconstr. Surg. 109, 1760–1761.
Petrova, V., Eva, R., 2018. The virtuous cycle of axon growth: axonal transport of growth-promoting machinery as an intrinsic determinant of axon regeneration. Dev. Neurobiol. 78, 898–925.
Pham, H., Tonai, R., Wu, M., Birtolo, C., Chen, M., 2018. CD73, CD90, CD105 and Cadherin-11 RT-PCR screening for mesenchymal stem cells from cryopreserved human cord tissue. Int. J. Stem Cells. https://doi.org/10.15283/ijsc17015.
Progatzky, F., Dallman, M.J., Lo Celso, C., 2013. From seeing to believing: labelling strategies for in vivo cell-tracking experiments. Interface Focus 3, 20130001.
Raimondo, S., Fornaro, M., Tos, P., Battiston, B., Giacobini-Robecchi, M.G., Geuna, S., 2011. Perspectives in regeneration and tissue engineering of peripheral nerves. Anatomischer Anzeiger: Official organ of the Anatomische Gesellschaft. 193, 334–340.
Rosberg, H.E., Carlsson, K.S., Dahlin, L.B., 2005. Prospective study of patients with injuries to the hand and forearm: costs, function, and general health. Scand. J. Plast. Reconstr. Surg. Hand Surg. 39, 360–369.
Ross, M.H., Pawlina, W., 2010. Histology: a Text and Atlas, With Correlated Cell and Molecular Biology, 6th edition. north america edition. Lippincott Williams and Wilkins.
Sanna, M.D., Ghelardini, C., Galeotti, N., 2017. Effect of amitriptyline treatment on neurofilament-H protein in an experimental model of depression. Brain Res. Bull. 128, 1–6.
Sasaki, R., Masuda, S., Nagao, M., 2000. Erythropoietin: multiple physiological functions and regulation of biosynthesis. Biosci. Biotechnol. Biochem. 64, 1775–1793. https://doi.org/10.1271/bbb.64.1775.
Savino, R., Ciliberto, G., 2004. A paradigm shift for erythropoietin: no longer a specialized growth factor, but rather an all-purpose tissue-protective agent. Cell Death Differentiation 1, 2–4.
Sekiguchi, Y., Kikuchi, S., Myers, R.R., Campana, W.M., 2003. Erythropoietin inhibits spinal neuronal apoptosis and pain following nerve root crush. Spine (Phila Pa 1976) 1 (28), 2577–2584.
Shu, Y., Yang, C., Ji, X., Zhang, L., Bi, Y., Yang, K., Gong, M., Liu, X., Guo, Q., Su, Y., Qu, X., Nan, G., Zhao, C., Zeng, Z., Yu, X., Zhang, R., Yan, S., Lei, J., Wu, K., Wu, Y., An, L., Huang, S., Gong, C., Yuan, C., Liu, W., Li, Y., 2018. Reversibly immortalized human umbilical cord–derived mesenchymal stem cells (UC-MSCs) are responsive to BMP9-induced osteogenic and adipogenic differentiation. J. Cell. Biochem. 119, 8872–8886.
Stenberg, L., Kanje, M., Dolezal, K., Dahlin, L.B., 2012. Expression of activating transcription factor 3 (ATF3) and caspase 3 in Schwann cells and axonal outgrowth after sciatic nerve repair in diabetic BB rats. Neurosci. Lett. 25 (515), 34–38.
Sundem, L., Chris Tseng, K.C., Li, H., Ketz, J., Noble, M., Elfar, J., 2016. Erythropoietin enhanced recovery after -Traumatic nerve injury: myelination and localized effects. J. Hand Surg. 41, 999–1010.
Taylor, C.A., Braza, D., Dillingham, T., Rice, J.B., 2008. The incidence of peripheral nerve injury in extremity trauma. Am. J. Phys. Med. Rehabil. 87, 381–385. https://doi.org/10.1097/PHM.0b013e31815e6370.
Wang, Z., Yang, X., Zhang, W., Zhang, P., Jiang, B., 2018. Tanshinone IIA attenuates nerve structural and functional damage induced by nerve crush injury in rats. PLoS One 13, 0202532. https://doi.org/10.1371/journal.pone.0202532.
Weiss, M.L., Medicetty, S., Bledsoe, A.R., Rachakatla, R.S., Choi, M., Merchav, S., Luo, Y., Rao, M.S., Velagaleti, G., Troyer, D., 2006. Human umbilical cord matrix stem cells: preliminary characterization and effect of transplantation in a rodent model of Parkinson's disease. Stem Cells 24, 781–792. https://doi.org/10.1634/stemcells.2005-0330.
Xiao, L., Tsutsui, T., 2013. Human dental mesenchymal stem cells and neural regeneration. Hum. Cell 26, 91–96.
Yang, C.C., Wang, Y., Chen, S.C., Jan, Y.M., Hsieh, Y.L., 2015. Enhanced functional recovery from sciatic nerve crush injury through a combined treatment of cold-water swimming and mesenchymal stem cell transplantation. Neurol. Res. 37, 816–826. https://doi.org/10.1179/1743132815Y.0000000060.
Zhuk, N., Kalyunov, V.N., 1997. Effect of nerve growth factor on the regeneration of fibers in the rat sciatic nerve. Neurosci. Behav. Physiol. 27, 541–544.