ORIGINAL ARTICLE
DOI: 10.5152/EssentDent.2026.26175

Prevalence, Patterns, and Treatment Strategies for Impacted Canines: A 10-Year Retrospective Study with a Retrospective Assessment of Hypothetical Cone Beam Computed Tomography Indications

Esra Mavi[1], Tuğçe Çevik Sönmez[2]

[1]Department of Oral and Maxillofacial Surgery, Faculty of Dentistry, Sivas Cumhuriyet University, Sivas, Türkiye
[2]Department of Oral and Maxillofacial Surgery, Faculty of Dentistry, Giresun University, Giresun, Türkiye

Cite this article as: Mavi E, Çevik Sönmez T. Prevalence, patterns, and treatment strategies for impacted canines: a 10-year retrospective study with a retrospective assessment of hypothetical cone beam computed tomography indications. *Essent Dent.* 2026, 5, 0175, doi:10.5152/EssentDent.2026.26175

Abstract

Background: This study aimed to investigate the prevalence and patterns of impacted canines and to question the necessity of 3-dimensional imaging techniques in evaluation.

Methods: A retrospective analysis of 175 impacted canines identified from panoramic radiographs and clinical records between 2013 and 2023 was conducted. All canine impactions were anatomically matched to the 7 categories listed in Yamamoto's classification, and transmigrated teeth were also noted. Two oral surgeons independently evaluated the radiographs for impacted canine positions, associated pathosis, and treatment procedures. The need for cone beam computed tomography (CBCT) was also retrospectively assessed as a hypothetical clinical indication based on panoramic findings.

Results: Most impacted canines were located in the maxilla (90.9%), and the majority of the sample consisted of canines in female patients (112 canines, 64.0%) compared with male patients (63 canines, 36.0%). Most cases were unilateral (73.7%). Type II impaction was the most common (54.9%) according to a standardized classification system. Transmigration occurred in 4 cases (2.3%), all in the mandible. Treatment varied by age ($P < .001$), with surgical exposure for orthodontic treatment more common in patients aged under 18 years, while extraction for prosthetic reasons or due to pathology/pain/infection was prevalent in older age groups. Cone beam computed tomography was retrospectively deemed indicated in 50.9% of cases, most commonly for evaluation of the labio-palatal position of the impacted canines.

Conclusion: This study emphasizes the importance of timely diagnosis and management of impacted canines. Panoramic radiographs remain useful for initial assessment, whereas CBCT should be used selectively when 2-dimensional (2D) imaging is inconclusive or when pathology is suspected. Yamamoto's classification should therefore be interpreted as a descriptive aid rather than evidence of the superiority of 2D imaging.

Keywords: Canine tooth, classification, prevalence, radiography, treatment

What is already known on this topic?

- *Impacted canines occur more frequently in the maxilla than in the mandible and are more common in female patients.*
- *Panoramic radiographs are routinely used for the diagnosis and initial evaluation of impacted canines, although they have limitations in assessing labio-palatal position and root resorption.*
- *Treatment options for impacted canines vary according to patient age, tooth position, and the presence of associated pathologies.*

What this study adds on this topic?

- *This study provides a detailed retrospective analysis of impacted canine patterns using Yamamoto's classification.*
- *It demonstrates a significant relationship between patient age and treatment choice, with orthodontic exposure preferred in younger patients and extraction in older age groups.*
- *The study highlights that the most common indication for additional cone beam computed tomography imaging is the assessment of the labio-palatal position of impacted canines, supporting selective rather than routine use of 3-dimensional imaging.*

Corresponding author: Tuğçe Çevik Sönmez
e-mail: tugce.cevik@giresun.edu.tr

Content of this journal is licensed under a Creative Commons Attribution-NonCommercial 4.0 International License.

Received: January 8, 2026
Revision Requested: March 2, 2026
Last Revision Received: July 6, 2026
Accepted: October 5, 2026
Publication Date: October 30, 2026

INTRODUCTION

Tooth impaction occurs when a tooth cannot emerge at the expected location in the dental arch during the usual eruption period. Impacted teeth result from an obstruction or abnormal position. Tooth transmigration is defined as at least half of the crown length of the impacted tooth crossing the midline. The prevalence of impacted teeth varies among populations, with the third molars, upper canines, upper central incisors, and premolars being the most commonly affected in that order, ranging from 6.9% to 76.6%.[1,2]

Impacted canines are common, more so in the upper jaw than the lower. Bilateral occurrence is seen in around 8% of maxillary cases. Maxillary canine impaction is observed in about 2% of the population, with a 2-fold prevalence in females.[3] Canine transmigration, rare, is more often found in the lower jaw. Its prevalence ranges from 0.1% to 0.34%.[4,5]

Impacted canines are attributed to local, systemic, and genetic factors. Local factors include reduced space due to tooth size and arch length discrepancies, as well as the presence of pathologies affecting both hard and soft tissues.[3,6]

Maxillary canines are crucial for facial aesthetics, arch development, and occlusion. Their management is challenging due to diverse inclinations and positions, requiring precision. Neglect may cause malalignment, adjacent tooth displacement, reduced arch length, resorption of neighboring teeth, enlarged follicles, cysts, infections, and referred pain. Timely intervention is crucial to prevent complications.[1,7,8,9]

Patients with impacted canines should be evaluated for malocclusion and suitable treatment options. These include autotransplantation, surgical exposure with or without orthodontic alignment, or extraction. Regular follow-ups are crucial for patients declining treatment. Orthodontic traction is generally avoided when ankylosis is suspected, when the canine position is severely unfavorable for orthodontic movement, when adequate arch space cannot be achieved, when there is advanced root dilaceration or marked risk to adjacent teeth, or if the patient declines treatment. Success rates for orthodontic management are lower in adults (41% in those over 30 years) compared to younger patients (100% in ages 20-30 years).[10]

Complications associated with the management of impacted maxillary and mandibular canine teeth include ecchymosis, infection, paresthesia, loss of the soft tissue flap, reduction in attached gingiva, pulp devitalization, damage to adjacent structures, and pain. Orthopantomograms are commonly used for diagnosis, but in some cases, cone beam computed tomography (CBCT) may be necessary for detailed insights into tooth position, root resorption, pathologies, and anatomical relationships.[11,12] Hajeer et al[13] demonstrated higher diagnostic accuracy of CBCT than conventional radiography for localization of impacted maxillary canines, supporting selective CBCT use when 2-dimensional (2D) imaging is inconclusive.

This study aims to explore the prevalence and patterns of impacted canines while examining the association of treatment methods and associated pathologies with variables such as age, gender, and jaw. Furthermore, the study seeks to assess the retrospective need for 3-dimensional (3D) imaging and to identify the clinical situations in which CBCT would be considered based on panoramic radiographic findings.

MATERIAL AND METHODS

Study Design

This retrospective analysis follows the strengthening the reporting of observational studies in epidemiology (STROBE) guidelines for observational studies and focused on patients with impacted canine teeth who applied to the Department of Oral and Maxillofacial Surgery, Faculty of Dentistry, Sivas Cumhuriyet University between January 1, 2013, and December 31, 2023. Before the retrospective review of patient records for research purposes commenced, the study was approved by the Sivas Cumhuriyet University Clinical Research Ethics Committee (Decision no: 2023-06/33, Date: June 22, 2023) in compliance with the Declaration of Helsinki. No records were accessed for research purposes before ethics approval. For the retrospective use of records, written informed consent had been obtained from the patients at the time of clinical care. As this was a retrospective radiographic study, no additional imaging or radiation exposure was performed for study purposes. Sample size was calculated using G*Power (version 3.1; Heinrich-Heine-Universität Düsseldorf, Germany). A priori power analysis was performed for the chi-square test of independence, assuming a medium effect size ($w = 0.30$), a significance level of $\alpha = 0.05$, and a statistical power of $1 - \beta = 0.90$ ($\beta = 0.10$). Based on these parameters, the minimum required total sample size was calculated as 175 impacted canines.[14]

Data Collection

The database was collected from panoramic radiographs and clinical records of patients receiving treatment for impacted canines and undergoing various surgical procedures:

- Orthodontic extrusion
- Orthodontic extraction
- Prosthetic extraction
- Extraction due to pathology/pain/infection
- Transplantation

Panoramic radiographs obtained from the Instrumentarium OP200 D (Instrumentarium Dental, Tuusula, Finland) device were evaluated. All patients' panoramic radiographs were examined carefully by 2 skilled oral and maxillofacial surgeons. Differences between examiners were resolved through

consensus and agreement.[4] After applying the selection criteria, 175 consecutive impacted canine cases meeting inclusion criteria were included. Inclusion criteria:

- Radiographically diagnosed impacted maxillary or mandibular permanent canine teeth;
- Quality panoramic radiographs taken pre-surgically;
- Patients aged 11 years or older;
- No structural anomalies or syndromes affecting the area.

Panoramic images displaying artifacts, positioning errors, or insufficient image quality that hindered a thorough examination were excluded from the study.

The impacted canine was considered the primary unit of analysis. Therefore, in patients with bilateral impaction, each impacted canine was analyzed as a separate observation. Consequently, the final sample comprised 175 impacted canines from 152 patients, including 46 canines from 23 patients with bilateral impaction. Patients' demographic information (gender, age) and treated tooth number were obtained from the records. Patients were divided into 3 groups: the first group from <18 years, the second group from 18-35 years, and the third group from >35 years.

The identification, screening, eligibility assessment, and final inclusion process are summarized in the study flow diagram (Figure 1).

Radiographic Analysis

Two experienced oral and maxillofacial surgeons independently evaluated all panoramic radiographs using Cliniview software (version 10.1; Instrumentarium Dental, Tuusula, Finland). The impacted tooth location (side/jaw) and unilateral/bilateral status were recorded. Position was classified into 7 types according to Yamamoto et al[15] based on the relationship between the long axis of the impacted canine and the occlusal plane. Linear measurements, including follicular space width, were carried out digitally using the software measurement tools. Follicular enlargement was defined as a pericoronal radiolucency exceeding 3 mm at its greatest width, measured digitally from the crown surface to the outer border of the follicular space on panoramic radiographs.[9] Because all images were obtained with the same panoramic unit and software, the 3-mm threshold was applied consistently across cases while acknowledging the inherent magnification of panoramic imaging. However, panoramic radiography has inherent magnification and distortion, and no patient-specific calibration object was available; therefore,

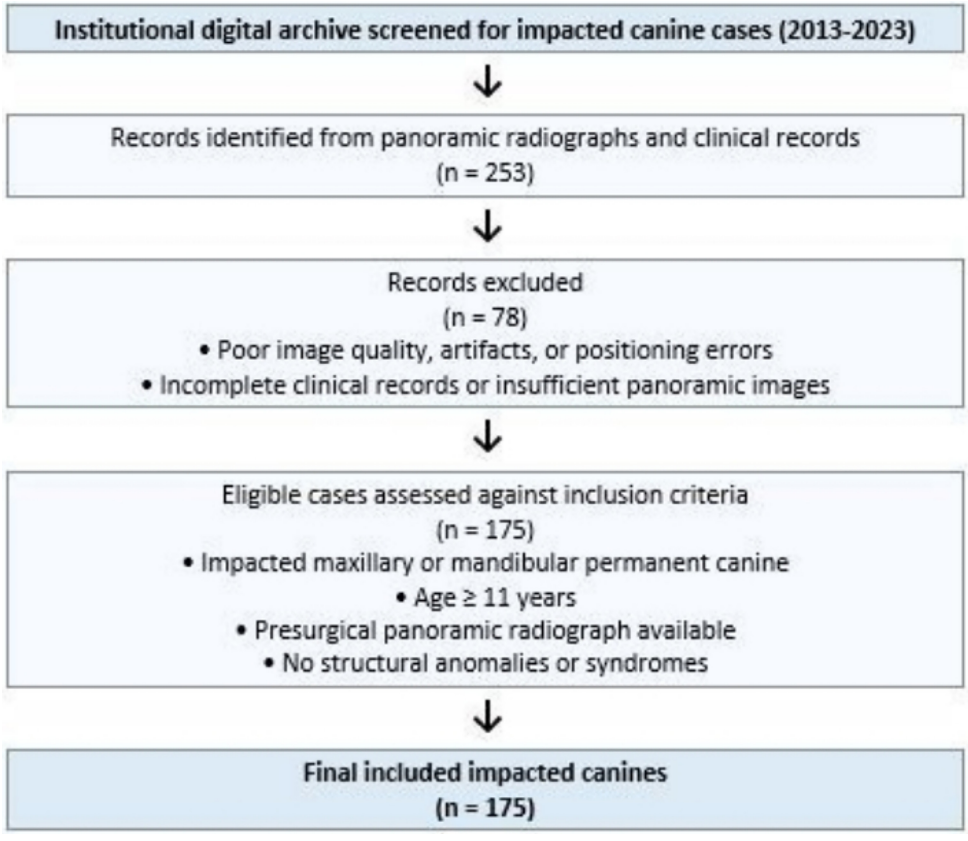

Figure 1. Flow diagram summarizing identification, eligibility assessment, exclusion criteria, and final inclusion of impacted canine cases from the institutional digital archive between 2013 and 2023.

follicular width was interpreted as a categorical screening finding rather than an exact morphometric outcome.

Type I: Vertical impaction—between the lateral incisor and first premolar.
Type II: Mesially inclined impaction against the occlusal plane.
Type III: Distally inclined impaction against the occlusal plane.
Type IV: Mesially oriented crown with horizontal impaction.
Type V: Distally oriented crown with horizontal impaction.
Type VI: Impaction in reverse.
Type VII: Labio-lingual (palatal) or ectopic impaction.

Transmigration was also recorded on panoramic radiographs when at least half of the canine crown crossed the midline.[2,4]

The complications observed regarding the impacted tooth were recorded according to the criteria below:

1. Root resorption
2. Enlargement of the dental follicle (>3 mm)
3. Presence of odontoma/local pathology
4. No complications

Additionally, the necessity of 3D examination (CBCT) was evaluated and, if necessary, which of the following indications will be recorded:

1. Evaluation of the labio-palatal position of the impacted canine tooth.
2. Determination of root resorption in the adjacent tooth.
3. Evaluation of the impacted canine follicle or associated pathological formation.
4. Evaluating anatomical structure.

Two oral and maxillofacial surgeons independently evaluated whether additional CBCT imaging would be clinically indicated for each impacted canine case. This assessment was based solely on 2D radiographic interpretation. No additional CBCT examinations were requested for the purpose of this study. The evaluation reflects a hypothetical clinical decision-making process rather than confirmation of whether CBCT was actually performed; therefore, CBCT-based confirmation of labial/palatal position or tooth-specific root-resorption patterns was outside the scope of this study. This approach should be interpreted as a diagnostic-decision simulation based on panoramic findings and not as verification of CBCT findings or actual CBCT utilization.

Statistical Analysis

Statistical package for the social sciences (SPSS) software (version 22, IBM Corporation, Armonk, NY, USA) was utilized for statistical analyses. Demographic characteristics are summarized using descriptive analyses, including frequencies and percentages. The associations between the qualitative variables were examined using the chi-square test. Kappa coefficient was calculated to evaluate interobserver agreement. Statistical significance was set at $P < .05$. To address the potential impact of violating the assumption of statistical independence in bilateral cases (23 patients, 46 impacted canines), a sensitivity analysis was performed at the patient level (N = 152) by selecting a single canine per patient. The sensitivity analysis yielded results consistent with the main analysis.

RESULTS

A total of 175 impacted canines from 152 patients were analyzed. The sample included 112 impacted canines in female patients (64.0%; 95% CI, 56.7%-70.7%) and 63 in male patients (36.0%; 95% CI, 29.3%-43.3%), with patient age ranging from 13 to 71 years (mean age: 33.37 ± 18.54 years). Age groups comprised 47 canines in patients aged < 18 years, 57 canines in patients aged 18-35 years, and 71 canines in patients aged > 35 years. Of these, 90.9% (n=159; 95% CI, 85.7%-94.3%) were maxillary and 9.1% (n=16; 95% CI, 5.7%-14.3%) were mandibular. Tooth 13 accounted for 45.7% (n=80), tooth 23 for 45.2% (n=79), tooth 33 for 5.7% (n=10), and tooth 43 for 3.4% (n=6). Bilateral impactions represented 46 canines in 23 patients (26.3% of canines; 95% CI, 20.3%-33.3%), all in the maxilla, while 73.7% (n=129; 95% CI, 66.7%-79.7%) were unilateral. No statistical gender difference was found in cases of bilateral impaction ($P=.203$).

Interobserver agreement for position classification was excellent (Cohen's kappa=0.88). The observed canine types are shown in Figure 2. The most prevalent category was type II (54.9%; 95% CI, 47.5%-62.0%). Type VI was not encountered at all. The least observed were type III (0.6%) and type V (0.6%). Type distribution was not significantly associated with sex (chi-square [6]=8.47, $P=.205$, Cramer's $V=0.220$) or side (chi-square [6]=6.35, $P=.385$, Cramer's V=0.191), whereas a significant association was observed with jaw (chi-square [6]=44.59, $P < .001$, Cramer's $V=0.505$). Transmigration was observed only in the mandible (Table 1). The mean age of patients with maxillary impacted canines was 32.91 ± 18.36 years, while it was 38.00 ± 20.36 years for those with mandibular impactions.

When 2 different surgeons evaluated complications caused by impacted canines on panoramic radiographs, there was no significant difference between observers ($P=.076$) (Figure 3). Additionally, there was good agreement between the observers in determining the complications (weighted kappa=0.713).

In patients, surgical exposure for orthodontic purposes was performed in 33.7% (n=59; 95% CI, 27.1%-41.0%), orthodontic extraction in 5.1% (n=9; 95% CI, 2.7%-9.5%), prosthetic extraction in 39.4% (n=69; 95% CI, 32.5%-46.8%), and surgical extraction due to pathology/pain/infection in 21.7% (n=38; 95% CI, 16.2%-28.4%) (Figure 4). No canine transplantation was performed. The distribution of age varied significantly across treatment groups. The mean

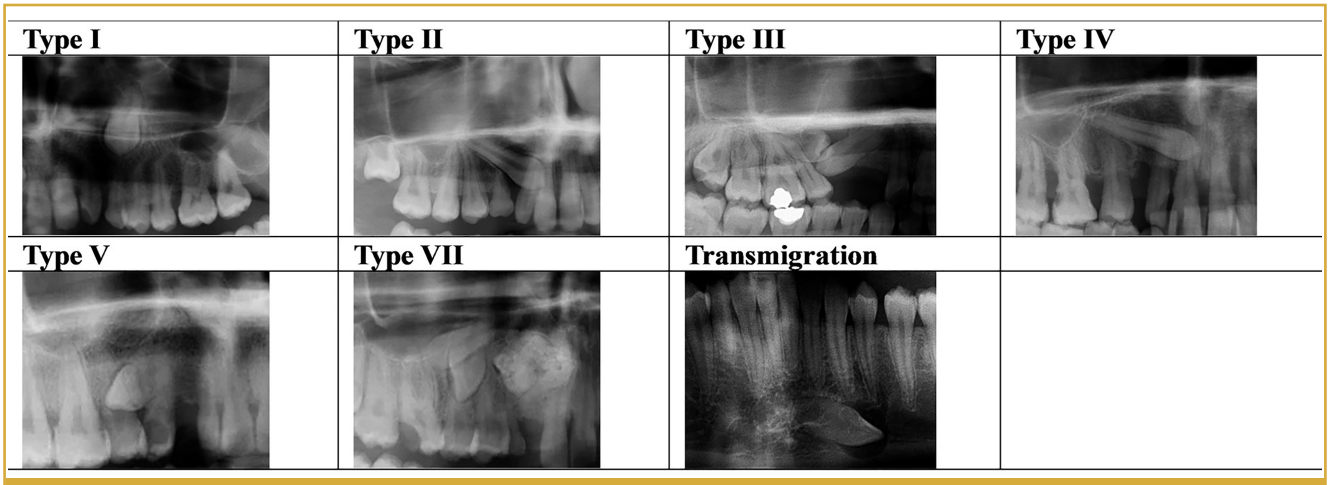

Figure 2. Representative panoramic radiographs showing the Yamamoto position categories (types I-VII) identified in this study and transmigration (TM) assessed in orthopantomograms (OPGs). Type VI was not encountered.

age was 16.96 ± 1.94 years for orthodontic extrusion, 17.77 ± 5.80 years for orthodontic extraction, 47.07 ± 14.87 years for prosthetic extraction, and 37.68 ± 18.45 years for extractions due to pathology/pain/infection.

The distribution of treatment choices across age groups (<18 years, n=47; 18-35 years, n=57; >35 years, n=71) differed significantly (chi-square (6)=112.03, *P* < .001, Cramer's V=0.566) (Table 2). In the patient-level sensitivity analysis (n = 152, one canine per patient), the direction and significance of all associations remained unchanged: position type was significantly associated with jaw (chi-square [6] = 38.97, P < .001, Cramer's V = 0.506) but not with sex (chi-square [6] = 6.64, P = .356) or side (chi-square [6] = 6.47, P = .372), and treatment choice remained significantly associated with age group (chi-square [6] = 93.43, P < .001, Cramer's V = 0.554).

The agreement between the surgeons was excellent in terms of the necessity of 3D examination with CBCT and indications (respectively, kappa value=0.817 and kappa value=0.878). Based on panoramic radiographic interpretation, CBCT was deemed clinically indicated in 50.9% of cases. These values reflect retrospective indication rather than confirmed CBCT acquisition. The distributions of the CBCT indications assigned by the surgeons are shown in Figure 5.

Discussion

Using panoramic radiographs, this 10-year retrospective study examined the age and gender distribution, treatment methods, locations, position types, complications, CBCT requirements, and hypothetical CBCT indications of impacted canines. It is important to note that the CBCT component should be interpreted as a diagnostic-decision simulation based on existing panoramic records, not as evidence that CBCT was performed or that panoramic imaging can replace CBCT when 3D information is clinically required. Impacted canines in individuals with malocclusion pose challenges for dentists in determining the need for surgical intervention. Orthodontic procedures and lengthy treatment periods, coupled with financial

Table 1. Frequency and Percentage of Impacted Canine Position According to Sex, Side, and Jaw

	Gender		Side		Region		
Type	Female, n (%)	Male, n (%)	Right, n (%)	Left, n (%)	Maxilla, n (%)	Mandible, n (%)	Total, N (%)
Type I	12 (10.7)	12 (19.0)	11 (12.8)	13 (14.6)	21 (13.2)	3 (18.8)	24 (13.7)
Type II	59 (52.7)	37 (58.7)	49 (57.0)	47 (52.8)	88 (55.3)	8 (50.0)	96 (54.9)
Type III	1 (0.9)	0 (0.0)	1 (1.2)	0 (0.0)	1 (0.6)	0 (0.0)	1 (0.6)
Type IV	28 (25.0)	13 (20.6)	17 (19.8)	24 (27.0)	41 (25.8)	0 (0.0)	41 (23.4)
Type V	1 (0.9)	0 (0.0)	1 (1.2)	0 (0.0)	1 (0.6)	0 (0.0)	1 (0.6)
Type VII	8 (7.1)	0 (0.0)	6 (7.8)	2 (2.2)	7 (4.4)	1 (6.3)	8 (4.6)
Tm	3 (2.7)	1 (1.6)	1 (1.2)	3 (3.4)	0 (0.0)	4 (25.0)	4 (2.3)
Total N (%)	112 (64)	63 (36)	86 (49.1)	89 (50.9)	159 (90.9)	16 (9.1)	175 (100.0)

All values are presented as frequencies with corresponding percentages in parentheses.
Distribution by sex: chi-square (6)=8.47, *P*=.205; by side: chi-square (6)=6.35, *P*=.385; by jaw: chi-square (6)=44.59, *P* < .001.
TM, transmigration.

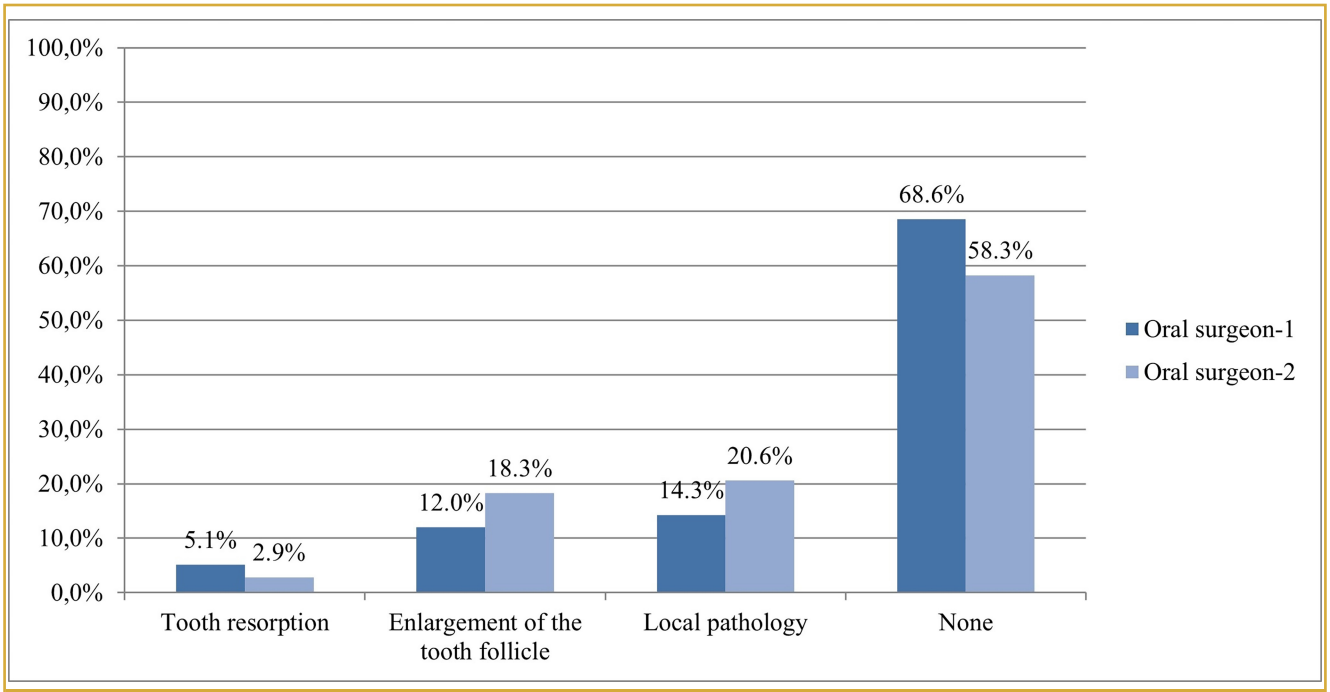

Figure 3. Distribution of radiographically detected complications associated with impacted canines on OPGs. OPGs, orthopantomograms.

burdens, can damage supporting tissues. Timely intervention is crucial to prevent severe complications.[16,17]

Most literature relies on 2D images to classify impacted maxillary and mandibular canines. Panoramic radiographs provide valuable information on dental age, symmetry, eruption sequence, pathology, and treatment response.[8,18,19] However, because labio-palatal position and early root resorption may be underestimated on panoramic images, they should be considered an initial rather than definitive imaging modality. Hajeer et al[13] demonstrated improved diagnostic accuracy of CBCT over conventional radiography for localization of impacted maxillary canines, supporting selective CBCT use when 2D imaging is inconclusive. Despite their limitations, panoramic radiographs are still widely used for diagnostics in the country and have been given priority in this study.

Impacted maxillary canines are relatively common. Impacted upper permanent canines are the most prevalent type of dental impaction, second only to third molars.[20] It is unusual for mandibular canine teeth to fail to erupt. Kamiloğlu et al[4] found that maxillary impaction to be significantly more frequent than mandibular impaction. Consistent with literature, only 16 out of 175 impacted teeth were in the mandible in this 10-year retrospective study.

In the study conducted by Hamozi et al,[17] the highest impaction was matched with type II (53.46%). type IV (27.22%), type I (17.82%), and type III (0.99%) were the next. In another study, type II was the most common (55.42%). There was also no type VI impaction.[15] In this study, consistent with previous studies, the most common category was type II (54.9%), followed by type IV (23.4%) and type I (13.7%). Type VI has never been found.

Mandibular impacted canines are the most commonly reported transmigrating tooth, but their incidence is low.[21,22] Kamiloglu et al[4] found only 2 transmigrated canines in 453 patients. Aktan et al[23] reported a prevalence of 0.34% for transmigrated mandibular canines and 0.14% for transmigrated maxillary canines. In this study, transmigration was found in 4 out of 175 impacted mandibular teeth, more prevalent in women (3 : 1 ratio), similar to findings of Aktan et al.[23]

When gender is taken into account, it is observed that female patients are more common. This gender disparity may be the consequence of variations in development patterns associated with sex.[24] In the study by Alyami et al,[25] the male : female ratio was 1 : 1.8. Consistent with literature, the male : female ratio was 1 : 1.7 in the current study. Canine unilateral impaction is more prevalent than bilateral impactions, according to prior researches.[18,24,25] Similarly, 26.3% (n=46) of the impacted teeth were bilateral (all observed in the maxilla), 73.7% (n=129) were unilateral in the study. Maxillary impaction was found to be extensive. Similar trends were observed in studies of Turkish patients, Aydin et al[22] reporting a maxilla-to-mandible impaction rate ratio of 7.47. In the current study, 90.9% (n=159) were in the maxilla, and 9.1% (n=16) were

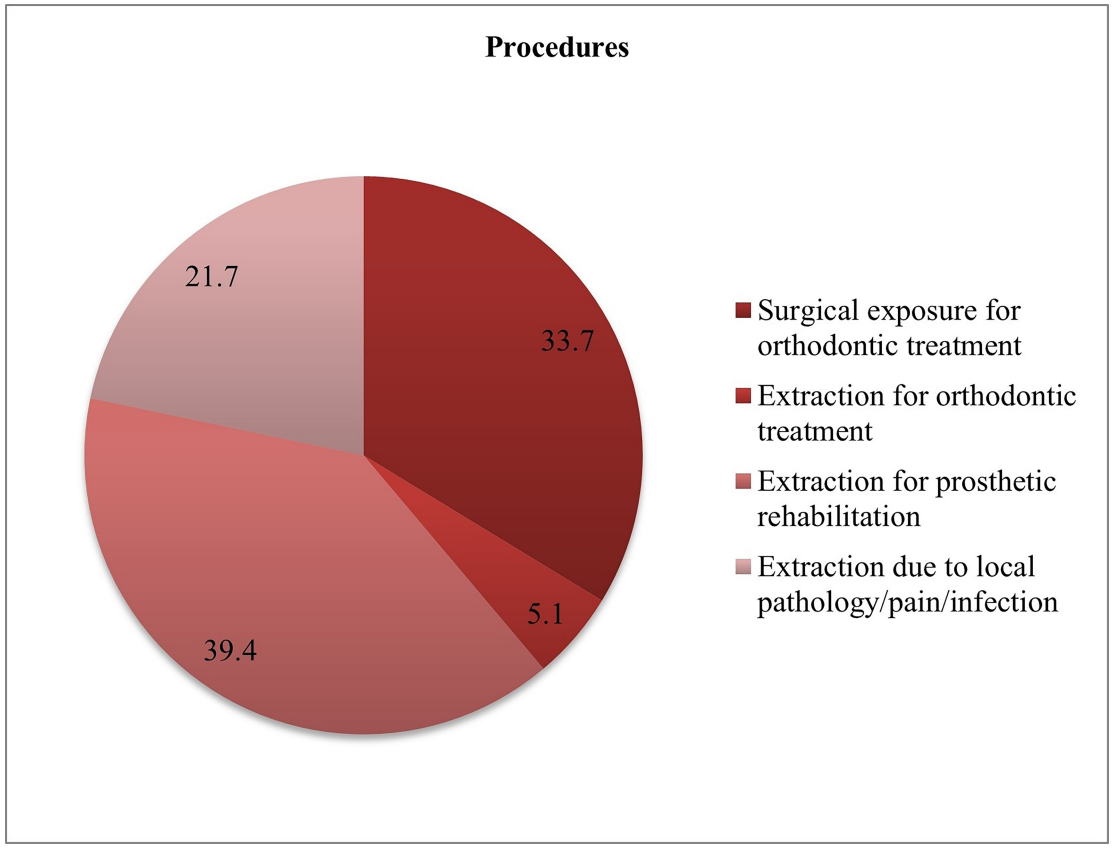

Figure 4. Distribution of treatment procedures for impacted canines by overall proportion of cases (%).

in the mandible, indicating a 9.9-fold difference between the maxilla and mandible. The small differences reported between studies may be attributed to differences in sample size or characteristics of the study population.

Yamamoto's classification simplifies impaction assessment and treatment planning but faces limitations in assessing labio-lingual relationships and precise root positions due to its 2D nature. Correlation with 3D imaging techniques (CBCT) is recommended. Alfailany et al[27] found that CBCT significantly improves 3D localization and detection of adjacent root resorption compared with 2D imaging, reinforcing the need to document clear clinical indications for CBCT.[15,26] In this study, the necessity of CBCT evaluation was questioned. The investigation was in line with Lai et al,[12] which found that the most frequent justification for CBCT was the labio-palatal location of the affected maxillary canine. In the aforementioned study, the assessors included orthodontists and surgeons. Remarkably, more oral surgeons than orthodontists (70 versus 4) said that an enlarged follicle is a reason for CBCT assessment. In this study, evaluation was performed only by oral surgeons, and the fact that the second most common reason for CBCT analysis was the enlargement of the dental follicle coincides with this situation.

Treatment of impacted canines is crucial for appearance and function. In this study, patients under 18 years more often

Table 2. Distribution of Treatment Choices According to Age Group

	Age Category, n (%)			
Procedures	<18	18-35	>35	*P*
Surgical exposure for orthodontic treatment	39 (66.1)	20 (33.9)	0 (0.0)	< .001*
Extraction for orthodontic treatment	5 (55.6)	4 (44.4)	0 (0.0)	
Extraction for prosthetic rehabilitation	0 (0.0)	17 (24.6)	52 (75.4)	
Extraction due to local pathology/pain/infection	3 (7.9)	16 (42.1)	19 (50.0)	

All values are presented as frequencies with corresponding percentages in parentheses. Overall association between age group and treatment choice: chi-square (6) = 112.03, $P < .001$, Cramer's $V = 0.566$.
Significance level: *$P \leq .001$ denotes a highly statistically significant association.

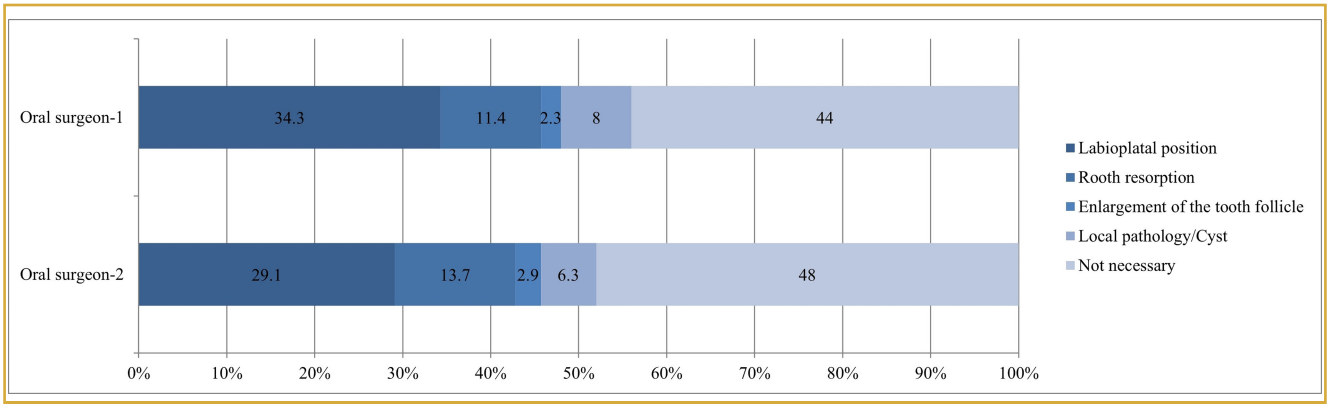

Figure 5. Distribution of hypothetical CBCT indication categories assigned by the oral surgeons on the basis of panoramic radiographic interpretation. CBCT, cone beam computed tomography.

underwent surgical exposure or extraction for orthodontic reasons, probably because interceptive management is more feasible at younger ages. By contrast, patients older than 35 years did not receive orthodontic treatment. Most extractions in that group were performed for prosthetic reasons (73.2%), whereas 26.8% were related to pathology/pain/infection, reflecting a preference for shorter and less costly treatment options. Clinically, these findings suggest that age and restorative context had a stronger influence on treatment choice than panoramic classification alone.

Local pathology was most common, followed by enlarged dental follicles, with root resorption being least frequent. Diagnosing root resorption of neighboring teeth on panoramic radiographs is more challenging than on 3D imaging.[8,28] The low frequency of root resorption detected in the present study may therefore reflect underdetection on panoramic imaging rather than a true absence of resorption, and this is a limitation of the study. Alsino et al[29] validated CBCT's superior accuracy for detecting dehiscence and fenestration, which supports cautious interpretation of complication rates derived from panoramic imaging alone. Additional limitations include the retrospective single-center design, canine-level rather than patient-level analysis, the absence of verified CBCT acquisition or CBCT-based confirmation of labial/palatal position, and the inability to derive tooth-specific resorption patterns from 3D imaging. In addition, panoramic magnification and distortion may affect linear follicular-width assessment, and continuous measurement error could not be analyzed because repeated continuous measurements were not archived as study variables. Therefore, the current findings should be interpreted as observational patterns that support the use of CBCT on panoramic radiography in a selective rather than routine manner when making treatment decisions. Thus, prospective studies with CBCT confirmation would be necessary before any practice change is advocated.

From a clinical standpoint, panoramic radiography remains appropriate as the first-line examination for many impacted canines, particularly when the tooth position and its relation to adjacent structures can be reasonably assessed on 2D imaging. Cone beam computed tomography should be considered selectively when the labio-palatal position is uncertain, when root overlap raises suspicion of adjacent tooth resorption, in ectopic/type VII or transmigrated canines, or when follicular enlargement or other pathology is suspected. This selective approach may improve diagnostic accuracy while limiting additional radiation exposure and cost; however, prospective CBCT-confirmed studies are required before practice-changing recommendations can be made.[12,28,29]

In conclusion, in this sample of impacted canine cases, most canines were maxillary, were observed in female patients, and were mainly type II impactions. Treatment varied by age, with younger patients often undergoing surgical exposure, while older patients commonly had extractions. Panoramic radiography provided useful descriptive information for initial assessment; however, because labio-palatal localization and root resorption may be underestimated on 2D imaging, CBCT should be used selectively when panoramic findings are inconclusive or pathology is suspected. Yamamoto's classification should therefore be interpreted as a descriptive aid within an observational framework rather than as a stand-alone determinant of treatment.

Data Availability Statement: The data that support the findings of this study are available on request from the corresponding author.

Artificial Intelligence Usage Statement: The authors used ChatGPT (OpenAI) to improve language and edit grammar and sentence structure during the preparation of the manuscript. The tool was not used to generate scientific content or interpret the study results.

Ethics Committee Approval: Ethical committee approval was received from the Ethics Committee of Sivas Cumhuriyet University (Approval no: 2023-06/33, Date: June 22, 2023).

Informed Consent: Written informed consent was obtained from the patients/patient who agreed to take part in the study.

Peer-review: Externally peer-reviewed.

Author Contributions: Concept – E.M., T.Ç.S.; Design – E.M., T.Ç.S.; Supervision – E.M.; Resources –E.M.; Materials – E.M., T.Ç.S.; Data Collection and/or Processing – E.M., T.Ç.S.; Analysis and/or Interpretation – T.Ç.S.; Literature Search – E.M., T.Ç.S.; Writing – E.M., T.Ç.S.; Critical Review – E.M., T.Ç.S.

Declaration of Interests: The authors have no conflicts of interest to declare.

Funding: The authors declare that this study received no financial support.

REFERENCES

1. Grisar K, Luyten J, Preda F, et al. Interventions for impacted maxillary canines: a systematic review of the relationship between initial canine position and treatment outcome. *Orthod Craniofac Res*. 2021;24(2):180-193. [CrossRef]
2. Mupparapu M. Patterns of intra-osseous transmigration and ectopic eruption of mandibular canines: review of literature and report of nine additional cases. *Dentomaxillofac Radiol*. 2002;31(6):355-360. [CrossRef]
3. Bedoya MM, Park JH. A review of the diagnosis and management of impacted maxillary canines. *J Am Dent Assoc*. 2009;140(12):1485-1493. [CrossRef]
4. Kamiloglu B, Kelahmet U. Prevalence of impacted and transmigrated canine teeth in a Cypriote orthodontic population in the Northern Cyprus area. *BMC Res Notes*. 2014;7:346. [CrossRef]
5. Camilleri S, Scerri E. Transmigration of mandibular canines—a review of the literature and a report of five cases. *Angle Orthod*. 2003;73(6):753-762. [CrossRef]
6. Margot R, Maria CL, Ali A, Annouschka L, Anna V, Guy W. Prediction of maxillary canine impaction based on panoramic radiographs. *Clin Exp Dent Res*. 2020;6(1):44-50. [CrossRef]
7. Manne R, Gandikota C, Juvvadi SR, Rama HRM, Anche S. Impacted canines: etiology, diagnosis, and orthodontic management. *J Pharm Bioallied Sci*. 2012;4(2)(suppl 2):S234-S238. [CrossRef]
8. Alqerban A, Jacobs R, Lambrechts P, Loozen G, Willems G. Root resorption of the maxillary lateral incisor caused by impacted canine: a literature review. *Clin Oral Investig*. 2009;13(3):247-255. [CrossRef]
9. Ericson S, Bjerklin K, Falahat B. Does the canine dental follicle cause resorption of permanent incisor roots? A computed tomographic study of erupting maxillary canines. *Angle Orthod*. 2002;72(2):95-104. [CrossRef]
10. Becker A, Chaushu S. Etiology of maxillary canine impaction: a review. *Am J Orthod Dentofacial Orthop*. 2015;148(4):557-567. [CrossRef]
11. Alberto PL. Management of the impacted canine and second molar. *Oral Maxillofac Surg Clin N Am*. 2007;19(1):59-68. [CrossRef]
12. Lai CS, Suter VGA, Katsaros C, Bornstein MM. Localization of impacted maxillary canines and root resorption of neighbouring teeth: a study assessing the diagnostic value of panoramic radiographs in two groups of observers. *Eur J Orthod*. 2014;36(4):450-456. [CrossRef]
13. Hajeer MY, Al-Homsi HK, Alfailany DT, Murad RMT. Evaluation of the diagnostic accuracy of CBCT-based interpretations of maxillary impacted canines compared to those of conventional radiography: an in vitro study. *Int Orthod*. 2022;20(2):100639. [CrossRef]
14. Avsever H, Gunduz K, Akyol M, Orhan K. Multicentre evaluation of impacted and transmigrated canines: a retrospective study [journal]. *Australas Orthod J*. 2017;33(2):170-178. [CrossRef]
15. Yamamoto G, Ohta Y, Tsuda Y, Tanaka A, Nishikawa M, Inoda H. A new classification of impacted canines and second premolars using orthopantomography. *Asian J Oral Maxillofac Surg*. 2003;15(1):31-37. [CrossRef]
16. Altan A, Çolak S, Akbulut N, Altan H. Radiographic features and treatment strategies of impacted maxillary canines. *Cumhuriyet Dent J*. 2020;23(1):32-37. [CrossRef]
17. Hamozi SM, Alghanim KM, Abdali Y. Prevalence and Classification of Maxillary Canine Impaction among Iraqi patients at An-Najaf City. *Indian J Forensic Med Toxicol*. 2020;14(1):540-543. [CrossRef]
18. Alqerban A, Willems G, Bernaerts C, Vangastel J, Politis C, Jacobs R. Orthodontic treatment planning for impacted maxillary canines using conventional records versus 3D CBCT. *Eur J Orthod*. 2014;36(6):698-707. [CrossRef]
19. da Silva Santos LM, Bastos LC, Oliveira-Santos C, da Silva SJA, Neves FS, Campos PSF. Cone-beam computed tomography findings of impacted upper canines. *Imaging Sci Dent*. 2014;44(4):287-292. [CrossRef]
20. Alamri A, Alshahrani N, Al-Madani A, Shahin S, Nazir M. Prevalence of impacted teeth in Saudi patients attending dental clinics in the eastern province of Saudi Arabia: a radiographic retrospective study. *ScientificWorldJournal*. 2020;2020:8104904. [CrossRef]
21. Gündüz K, Çelenk P. The incidence of impacted transmigrant canines: a retrospective study. *Oral Radiol*. 2010;26(2):77-81. [CrossRef]
22. Aydin U, Yilmaz HH, Yildirim D. Incidence of canine impaction and transmigration in a patient population. *Dentomaxillofac Radiol*. 2004;33(3):164-169. [CrossRef]
23. Aktan AM, Kara S, Akgünlü F, Malkoç S. The incidence of canine transmigration and tooth impaction in a Turkish subpopulation. *Eur J Orthod*. 2010;32(5):575-581. [CrossRef]
24. Melha SB, Alturki S, Aldawasri G, Almeshari N, Almeshari SKA, Albadr K. Canine impaction among Riyadh population: a single center experience. *Int J Oral Health Sci*. 2017;7(2):93-95. [CrossRef]
25. Alyami B, Braimah R, Alharieth S. Prevalence and pattern of impacted canines in Najran, South Western Saudi Arabian population. *Saudi Dent J*. 2020;32(6):300-305. [CrossRef]
26. Zuccati G, Ghobadlu J, Nieri M, Clauser C. Factors associated with the duration of forced eruption of impacted maxillary canines: a retrospective study. *Am J Orthod Dentofacial Orthop*. 2006;130(3):349-356. [CrossRef]
27. Alfailany DT, Shaweesh AI, Hajeer MY, Brad B, Alhaffar JB. The diagnostic accuracy of cone-beam computed tomography and two-dimensional imaging methods in the 3D localization and assessment of maxillary impacted canines compared to the gold standard in-vivo readings: a cross-sectional study. *Int Orthod*. 2023;21(3):100780. [CrossRef]
28. Alqerban A, Jacobs R, Fieuws S, Willems G. Comparison of two cone beam computed tomographic systems versus panoramic imaging for localization of impacted maxillary canines and detection of root resorption. *Eur J Orthod*. 2011;33(1):93-102. [CrossRef]
29. Alsino HI, Hajeer MY, Alkhouri I, Murad RMT. The diagnostic accuracy of cone-beam computed tomography (CBCT) imaging in detecting and measuring dehiscence and fenestration in patients with Class I malocclusion: a surgical-exposure-based validation study. *Cureus*. 2022;14(3):e22789. [CrossRef]