

Biotechnic & Histochemistry

ISSN: 1052-0295 (Print) 1473-7760 (Online) Journal homepage: https://www.tandfonline.com/loi/ibih20

Use of selenium to ameliorate doxorubicin induced hepatotoxicity by targeting pro-inflammatory cytokines

Ozge Cengiz, Munevver Baran, Esra Balcioglu, Pinar Alisan Suna, Pınar Bilgici, Ozge Goktepe, Gozde Ozge Onder, Rumeysa GOC & Arzu Yay

To cite this article: Ozge Cengiz, Munevver Baran, Esra Balcioglu, Pinar Alisan Suna, Pınar Bilgici, Ozge Goktepe, Gozde Ozge Onder, Rumeysa GOC & Arzu Yay (2020): Use of selenium to ameliorate doxorubicin induced hepatotoxicity by targeting pro-inflammatory cytokines, Biotechnic & Histochemistry, DOI: 10.1080/10520295.2020.1760353

To link to this article: https://doi.org/10.1080/10520295.2020.1760353

Published online: 13 May 2020.

Submit your article to this journal

Article views: 77

View related articles

View Crossmark data

Full Terms & Conditions of access and use can be found at
https://www.tandfonline.com/action/journalInformation?journalCode=ibih20

BIOTECHNIC & HISTOCHEMISTRY
https://doi.org/10.1080/10520295.2020.1760353

Taylor & Francis
Taylor & Francis Group

Check for updates

Use of selenium to ameliorate doxorubicin induced hepatotoxicity by targeting pro-inflammatory cytokines

Ozge Cengiz[a], Munevver Baran[b], Esra Balcioglu[a,c], Pinar Alisan Suna[a], Pınar Bilgici[a], Ozge Goktepe[a], Gozde Ozge Onder[a], Rumeysa GOC[a], and Arzu Yay[a,c]

[a]Faculty of Medicine, Department of Histology and Embryology, Erciyes University, Kayseri, Turkey; [b]Department of Pharmaceutical Basic Science, Faculty of Pharmacy, Erciyes University, Kayseri, Turkey; [c]Genome and Stem Cell Center (GENKOK), Erciyes University, Kayseri, Turkey

ABSTRACT

Doxorubicin (DOX) is a widely used drug for the treatment of cancer,but its clinical use is limited by its liver toxicity. Administering DOX with an antioxidant has become a strategy for preventing the side effects of DOX. Although selenium (Se) is an important trace mineral, data concerning the effect of Se on DOX induced liver tissue are lacking. We investigated the mechanism of DOX hepatotoxicity and the protective effect of different doses of Se on Dox induced liver damage. Female Wistar albino rats were divided into eight equal groups. Se was injected intraperitoneally (i.p.) to rats at doses of 0.5, 1, and 2 mg 0.5 h after injection i.p. of 5 mg/kg DOX on days 1, 7, 14, 21 and 28. Liver histopathology was assessed to determine the dose at which Se may best inhibit Dox induced liver toxicity,. Also, tumor necrosis factor-α (TNF-α), interleukin-1β (IL-1β) expression levels and proliferating cell nuclear antigen (PCNA) activity were determined using immunohistochemistry. We found that DOX caused liver damage and increased TNF-α, IL-1β and PCNA levels. Se prevented structural damage to liver tissues. Our findings reinforce the protective effects of Se in rat liver.

KEYWORDS

Doxorubicin; hepatotoxicity; liver; pro-inflammatory cytokines; rats; selenium

Radiotherapy and chemotherapy are the primary treatment options for many types of cancer. Despite their anti-tumor effects, both can be toxic to normal tissues; their adverse effects frequently outweigh their clinical advantages (Martinet Lamas et al. 2015). Doxorubicin (DOX), an anthracycline, is an effective antitumor drug. Dox is used to treat many malignancies including hematological malignancies, many types of carcinoma, and soft tissue sarcomas and solid tumors (Mazevet et al. 2013). Dox is toxic, however, to nerves (Tangpong et al. 2011), heart (Ascensao et al. 2012) and liver (Mete et al. 2016). Dox induced hepatotoxicity is due to oxygen radical injury to hepatic cell membrane lipids. Membrane lipid oxidation causes structural and functional alterations that produce hepatocyte apoptosis or necrosis and increase hepatic enzymes in the blood (Saad et al. 2001; Jung et al. 2014). Experimental animals treated with DOX become edematous with intracellular degeneration in the liver (Ingawale et al. 2014). Proposed mechanisms of DOX induced tissue damage include DNA breaks, lipid oxidation, inhibition of protease activity, disruption of cytoskeleton and extracellular matrix, and inhibition of the topoisomerase II-mediated re-formation of broken DNA strands (Paczek et al. 1992; Coers et al. 1994).

It is useful to employ antioxidants with DOX treatment to minimize the toxic effects on normal cells. Selenium (Se) is an essential trace element that is supplied in the diet. Se exhibits catalytic and structural functions and is an integral part of many proteins (Rayman 2002). Se has been reported to play a role in cancer prevention and immune response (Jia et al. 2015). Se in mammalian cells participates in the active site of antioxidant enzymes, e.g. glutathione peroxidase (Flora et al. 2002). The protective effect of Se is due to its ability to reduce intracellular reactive oxygen species (ROS), repair DNA fragmentation and suppress caspase and apoptosis signal-regulating kinase 1 activity (Takahashi et al. 1986). Se alone or combined with other antioxidants have been reported to exhibit detoxification effects in cases of exposure to various chemical agents (Soudani et al. 2011; Ognjanovic et al. 2012). Se likely exerts its effect via the Se-dependent glutathione peroxidase; however, protective mechanisms of Se appear to vary among organs. On the other hand, high dose Se induced toxicity and even lethality have been reported (Stajn et al. 1997).

DOX interferes with biochemical functions within cells, but the precise mechanism of both therapeutic and toxic effects remains controversial (Gewirtz 1999;

CONTACT Arzu Yay arzu.yay38@gmail.com Department of Histology and Embryology, Medicine Faculty, University of Erciyes, Kayseri, Turkey, 38039

© 2020 The Biological Stain Commission

Minoti et al. 2004; Nagai et al. 2016) Hepatotoxicity is a serious complication of DOX treatment (Mansouri et al. 2017). The use of antioxidant agents with DOX may be an appropriate approach to reducing its toxic side effects. We investigated whether different doses of Se may protect against DOX hepatotoxicity using histochemistry and immunohistochemistry (IHC).

Materials and methods

Animals

We used 64 200–250 g female Wistar albino rats obtained from the Experimental and Clinical Research Center of Erciyes University. Animals were housed in individual standard metal cages in a well-ventilated room at 22 ± 1 °C with a 12 h light:12 h dark cycle. Animals were provided with a standard laboratory diet and water *ad libitum*. Animals were adapted to their environment for at least 10 days before initiation of the experiment. The experimental protocol complied with the guidelines for animal experimentation and was approved by the Ethical Committee of the Medical Research of the National Research Center.

Chemicals and treatments

Animals in the DOX groups were given 5 mg/kg Dox intraperitoneally (i.p.) (Saba Pharmaceutical Industry, Istanbul, Turkey) on days 1, 7, 14, 21, 28. Se (Sigma–Aldrich, St. Louis, MO) was injected i.p. before DOX administration for the DOX + Se groups. Se was dissolved in saline and given daily for 28 days.

Experimental design

The rats were divided randomly into eight groups of eight animals. The control group was given 1 ml/kg saline. The DOX group rats were injected i.p. with 5 mg/kg DOX. The rats in the Se 1 group were injected i.p. daily with 0.5 mg/kg Se for 28 days. The rats in the Se 2 group were injected i.p. daily with 1 mg/kg Se and the rats in the Se 3 group rats were injected i.p. daily with 2 mg/kg Se for 28 days. The rats in the DOX + 0.5 mg Se group were given 5 mg/kg DOX once/week (five injections over 28 days), while 0.5 mg/kg Se was administered daily for 28 days. Similarly, the rats in the DOX + 1 mg Se group received 5 mg/kg/week DOX and 1 mg/kg Se was administered daily for 28 days. Rats in the DOX + 2 mg Se group received 5 mg/kg/week DOX and 2 mg/kg Se for 28 days. On day 5 after the last DOX application (day 33). The rats were sacrificed by decapitation under 50 mg/kg ketamine and 10 mg/kg xylazine anesthesia. The abdomen was opened and the liver was removed and fixed in 10% formaldehyde for histopathological and IHC examination.

Histopathology

The liver was excised from each animal and the lobes were cut longitudinally. Specimens were fixed in 10% formaldehyde for 24 h. Specimens were dehydrated through graded concentrations of ethanol, cleared with xylol and embedded in paraffin wax. Sections were cut at 5 µm were cut from each paraffin block. Histopathological changes were observed using hematoxylin and eosin (H & E), Masson's trichrome (MT), and periodic acid-Schiff (PAS) staining. H & E staining was used to detect structural changes. Masson staining was used to detect collagen to verify formation of fibrous tissue (Gao et al. 2019). PAS was used to visualize glycogen in hepatocytes as an indicator of normal hepatocyte function (Hui et al. 2017).

After staining, the sections were observed using a light microscope (BX-51; Olympus, Tokyo, Japan) and images were captured. At least five microscopic fields were evaluated to score the samples. The criteria for liver damage included dilation of sinusoids, hepatocyte vacuolization and pyknotic hepatocyte nuclei. Each sample was scored as 0, none; 1, mild; 2, moderate; 3, severe for each criterion. Histopathological examination and scoring were performed by an observer blinded to the identity of the experimental groups (Kart et al. 2010).

IHC

We used IHC kits to investigate anti-tumor necrosis factor-alpha (TNFα), interleukin-1 β (IL1-β) and proliferating cell nuclear antigen (PCNA) activity. Sections were analyzed using the avidin-biotin-peroxidase method (Thermo Scientific, Waltham, MA) following the manufacturer's recommendations. Liver sections were deparaffinized and rehydrated through descending alcohols. Endogenous peroxidase activity was blocked with 3% hydrogen peroxide for 10 min. The specimens were washed several times with PBS and antigen retrieval was performed by microwave treatment in 0.01 M sodium citrate buffer, pH 6.0, at 95 °C for 10 min. Sections were incubated with TNF-α antibody diluted 1:50 (sc.25280; Santa Cruz Biotechnology, Santa Cruz, CA), IL-1β diluted 1:100 (NBP1-19-775;Novus Biological, Littleton, CO), or PCNA diluted 1:100 (Ab6671; Abcam, Cambridge, MA) primary antibody at 4 °C overnight. Sections were rinsed with PBS and biotinylated secondary antibodies were applied for 15 min in a humidified chamber at room temperature.

Sections then were rinsed with PBS and incubated with 3,3′ p-diaminobenzidine tetrahydrochloride (DAB) (Thermo Scientific, Waltham, MA) as chromogen for 3–5 min at room temperature. After washing with deionized water, sections were counterstained with Gill's hematoxylin, rinsed with tap water, coverslipped and observed using a light microscope.

The TNF-α and IL-1β immunoreactivity intensities for each section were calculated as the mean immunoreactivity intensity using Image J software (National Institutes of Health, Besthesda, MD). The number of PCNA stained cells was counted using Image J software in ten random microscopic fields.

Statistical analysis

Statistical analysis was performed in SPSS 22 software (SPSS for Windows, Chicago, IL). The normal distribution of numerical variables was evaluated by the Shapiro-Wilk test. Comparisons between the groups were made by one-way analysis of variance for variables with normal distribution, and in case of differences, multiple comparisons were made using the Tukey test. For the non-normal distribution variables, comparisons between groups were made by Kruskal-Wallis analysis; if there was a difference, multiple comparisons were made using the Mann Whitney U test. Statistical significance level was set at $p \leq 0.05$.

Results

Histology

We observed normal liver architecture and hepatic cells with well-preserved cytoplasm and nucleus in liver sections from control rats (Figure 1). After DOX treatment, we found severe necrosis, sinusoid dilation, congested blood vessels, mononuclear cell infiltration and disruption of hepatic architecture. Administration of 0.5 or 1 mg Se produced no pathological changes; the liver tissue appeared similar to the control. The 2 mg Se group exhibited sinusoid dilation and mononuclear cell infiltration. In the DOX + 0.5 mg Se and DOX + 1 mg Se groups, both parenchyma and serosa appeared normal. Necrosis and moderate degeneration of liver parenchyma were observed in liver tissues of the DOX + 2 mg Se group (Figure 1). Histopathological changes in all groups are reported in Table 1.

Masson trichrome staining was used to determine the general appearance of connective tissue and collagen deposition (Figure 1). Normal connective tissue supporting the vein and portal area were observed on the wall of vena centralis and adjacent vessels in the liver sections of the control, 0.5 mg Se and 1 mg Se groups. In the DOX group, collagen fibers around the portal area were increased compared to the control group. Confluent fibrosis (bridging fibrosis) connecting the anatomical structures in the liver was observed in the DOX group. Little or no fibrosis was detected in the DOX + 0.5 mg Se and DOX + 1 mg Se groups, although

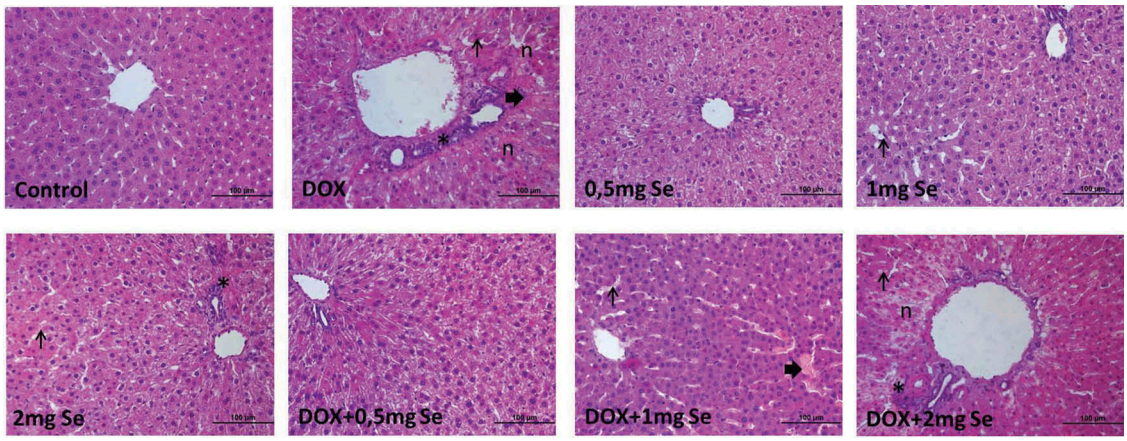

Figure 1. Effects of different Se doses on histological changes in the liver caused by DOX. n, necrosis; arrow, sinusoid dilation; thick arrow, congestion; star, mononuclear cell infiltration. H & E. x 400.

Table 1. Statistical analysis of histopathological scoring.

Control	0.5 mg Se	1 mg Se	2 mg Se	DOX	DOX + 0.5 mg Se	DOX + 1 mg Se	DOX + 2 mg Se	*p*
0.27 ± 0.46^{a}	0.45 ± 0.52^{a}	0.55 ± 0.68^{a}	$0.91 \pm 0.70^{a,c}$	$2.18 \pm 0.60^{b,c}$	$0.73 \pm 0.78^{a,c}$	$1.09 \pm 0.94^{a,c}$	1.55 ± 0.82^{c}	0.05

The same letters on the same line indicate similarity between groups and different letters indicate difference between groups.

moderate to severe fibrosis was found in the DOX + 2 mg liver tissues (Figure 2).

PAS stained sections showed dense glycogen staining in the hepatocytes of the control group. In the DOX and DOX + 2 mg Se groups, PAS staining was common in hepatocytes located close to the portal areas, while the cells around the central vein exhibited decreased glycogen content compared to controls. Glycogen content of hepatocytes appeared normal in liver tissue of the 0.5 and 1 mg Se groups. In the DOX + 0.5 mg Se and DOX + 1 mg Se groups, PAS staining was normal; treatment with Se increased the glycogen content compared to the DOX group. (Figure 2).

IHC

We used the avidin-biotin-peroxidase method for TNF-α and IL1-β IHC staining of liver tissue. We found that IL1-β expression was weak in the control tissues. We found that liver sections of the DOX group exhibited greater IL1-β immunostaining in hepatocytes compared to controls ($p < 0.001$). We also found that IL1-β immunoreactivity was decreased in the DOX + 0.5 mg Se group compared to DOX tissues, but the difference was not statistically significant (Figure 4; Table 2).

We found minimal expression of the inflammatory marker, TNF-α, in the the control group compared to all other experimental groups. By contrast, we found that staining was significantly greater in the hepatocytes of the 2 mg Se groups than for the control group ($p < 0.001$). The DOX and DOX + 2 mg Se groups exhibited increased TNF-α immunoreactivity compared to control tissues ($p < 0.001$) (Table 2). IHC staining of TNF-α was quantified as mean density of the stained regions using the Image J software analysis and the results are reported in Figure 5.

We performed PCNA IHC to detect DOX induced hepatocyte proliferation. In the DOX treated group, PCNA expression was increased for all experimental groups. PCNA stained nuclei were decreased significantly in the DOX and DOX + 2 mg Se groups

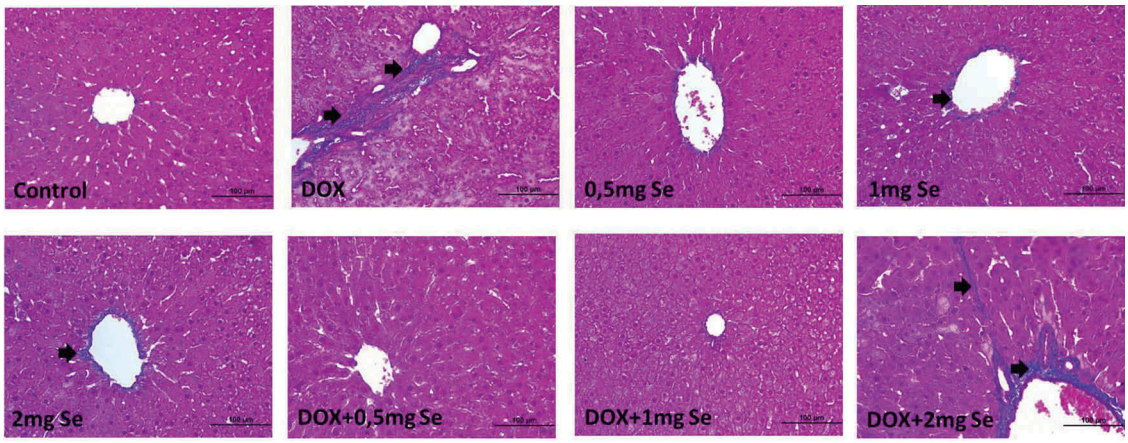

Figure 2. Liver tissue of all experimental groups stained with Masson's trichrome. Thick arrow, fibrosis. x 400.

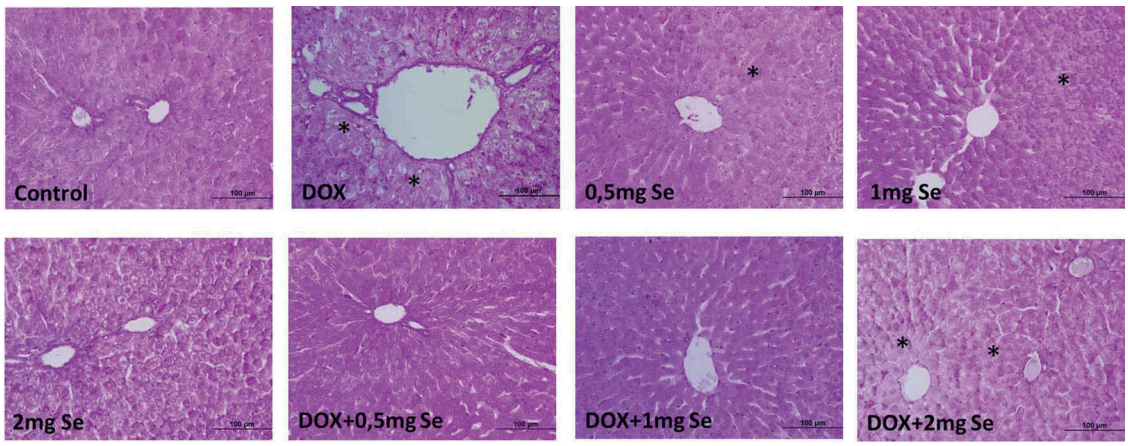

Figure 3. Liver tissue of all experimental groups stained with PAS. Star, reduced glycogen content in hepatocytes. x 400.

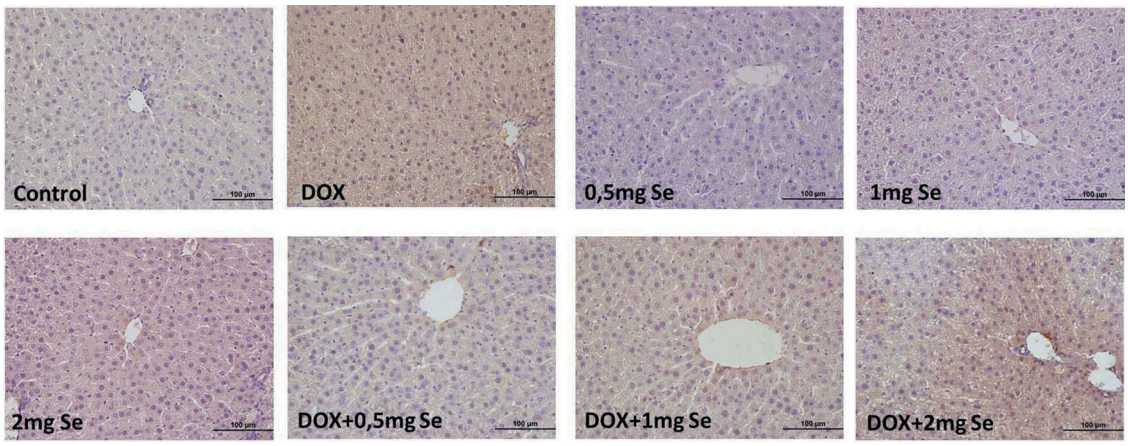

Figure 4. IHC staining of IL-1β in rat liver from control, 0.5 mg Se, 1 mg Se, and DOX + 0. 5 mg Se groups exhibit no expression. DOX without Se treatment exhibit a significant increase in IL-1β immunoreactivity in the hepatocytes compared to the control group. DOX + 0.5 mg Se group exhibit a significant reduction in IL-1β immunostaining compared to the DOX group. The DOX + 1 mg Se group exhibits lower IL-1β expression than the DOX group. The DOX + 2 mg group exhibits moderate IL-1β expression. Brown color indicates IL-1β staining. x 400.

Table 2. Immunoreactivity intensity for IL-1β, TNF-α and PCNA.

	Control	0.5 mg Se	1 mg Se	2 mg Se	DOX	DOX + 0.5 mg Se	DOX + 1 mg Se	DOX + 2 mg Se	*p*
IL-1β	76.5 ± 4.4^{a}	80.4 ± 4.1^{b}	80.3 ± 4.8^{b}	81.6 ± 4.1^{b}	81.0 ± 3.9^{b}	78.6 ± 4.2^{a,b}	80.7 ± 3.5^{b}	81.2 ± 3.3^{b}	0.001
TNFα	76.2 ± 4.4,^{ad}	79.9 ± 3.4^{a,b,d}	80.4 ± 4.3^{b,d}	82.1 ± 4.8,^{bc}	84.5 ± 6.7 ^{c}	78.9 ± 5.7^{a,b,d}	78.2 ± 3.8^{d}	81.8 ± 4.7$^{b–d}$	0.001
PCNA	2.0 (1.7–4.0)^{a,b}	2.0 (1.0–3.25)^{a}	2.0 (1.7–6.0)$^{a–c}$	4.0 (3.0–0.25)^{b,c}	5.0 (3.0–6.0)^{c}	4.0 (2.0–5.0)$^{a–c}$	3.5 (2.0–4.25)$^{a–c}$	5.0 (4.0–0.25)^{b,c}	0.001

The same letters on the same line indicate similarity between groups and different letters indicate difference between groups.

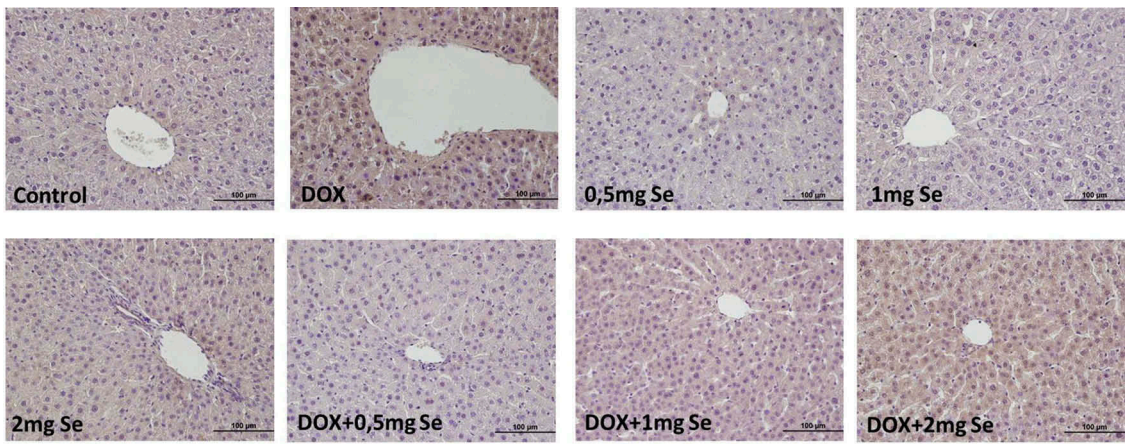

Figure 5. Immunoreactivity intensity of TNF-α in rat liver from control, 0.5 mg Se, 1 mg Se, and DOX + 0.5 mg Se groups are lower than for DOX group. DOX group TNF-α expression was strong compared to other groups. The DOX + 2 mg Se group exhibits moderate TNF-α immunoreactivity. Brown color indicates TNF-α staining. x 400.

compared to control rats ($p < 0.001$ for both comparisons) (Figure 6). No significant difference in the number of PCNA stained cells was observed among control, DOX + 0.5 mg Se and DOX + 1 mg Se groups (Table 2).

Discussion

We investigated the effects of different doses of Se as an anti-inflammatory agent and evaluated its potential protective effect against DOX induced liver injury in rats. We found that the administration of 0.5 mg Se decreased the level of TNF-α and IL1-β in the liver. We also found that treatment with 0.5 and 1 mg Se decreased Dox induced inflammation and cell damage; 2 mg Se exhibited no beneficial effect.

DOX is an effective anti-cancer agent that commonly is used to treat solid malignancies despite its wide range of side effects. DOX can cause liver damage by forming free

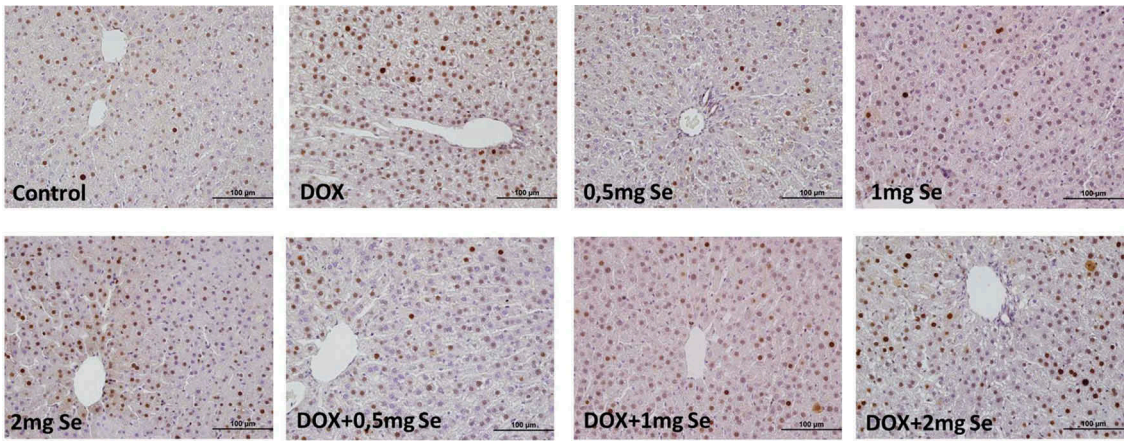

Figure 6. PCNA immunostained cells in liver of control groups are fewer than for the DOX group. DOX group exhibits an increased number of PCNA stained cells compared to other groups. DOX + 0.5 mg Se group exhibits a significant reduction in the number of PCNA stained cells compared to the DOX group. DOX + 1 mg Se and DOX + 2 mg Se groups exhibit moderate PCNA staining. Brown color indicates PCNA staining. x 400.

radicals that cannot be removed by the organism (Stehbens 2003; Alshabanah et al. 2010). Hepatocytes are rich in mitochondria and exhibit high respiratory activity (Barogi et al. 2000); therefore, the liver is susceptible to DOX toxicity because of its high metabolic acivity (Tacar et al. 2013).

When hepatocytes are injured, membrane permeability and transport function are altered (Mohan et al. 2011). Because the liver is responsible for most drug metabolic transformation and clearance, it is likely to be affected by DOX treatment. Hepatic injury due to DOX treatment is indicated by increased levels of hepatic oxidative stress, mitochondrial dysfunction, DNA damage and signs of cell death (Patel et al. 2010; Pereira et al. 2012). Histopathological evidence of DOX toxicity includes vascular congestion, sinusoid dilation, mononuclear cell infiltration and hepatocyte degeneration. Therefore, DOX appears to cause hepatotoxicity by the generation of free radicals that deplete the antioxidant defense system (Rashid et al. 2013).

Previous reports indicate that Dox induced oxidative stress could increase the expression of endothelial growth factors, which could increase the mitotic activity of epithelial cells lining the bile ducts to cause biliary hyperplasia and associated inflammatory cell infiltration (Mete et al. 2016). Histological abnormalities in rats treated with 1 mg/kg DOX included the breakdown of hepatic plates and the formation of necrotic hepatocytes (EI-Sayyad et al. 2009). We observed severe necrosis, mononuclear cell infiltration in the necrotic region, and intermittent hemorrhage in interstitial vessels in DOX treated animals.

Se participates in antioxidant defense, anticancer effects and detoxification (Zhang et al. 2013). Se can prevent free radicals from damaging cells in vivo. Se also exhibits anti-proliferative, anti-inflammatory and immunological effects (Huang et al. 2012; Mocchegiani et al. 2014). A significant decrease in Se level increases the susceptibility of tissues to oxidative stress (Bordoni et al. 2008). In humans, low dietary Se can cause problems due to oxidative stress including reproductive system disorders, cardiovascular diseases, decreased immunity and increased risk of cancer (Huang et al. 2012; Mocchegiani et al. 2014; Lance et al. 2017). On the other hand, excess dietary Se can be toxic (Bardia et al. 2008; Stemm et al. 2008).

Co-administration of Se and DOX decreases elevated serum ALT (Simoni et al. 1995). Se supplementation may reduce hepatotoxicity by rendering hepatic tissues less susceptible to lipid oxidation (Bulucu et al. 2009). This biochemical finding is supported by histopathological examination. We found that pre-treatment with 0.5 mg and 1 mg Se decreased significantly the degenerative and vascular changes caused by DOX. Also, 0.5 and 1 mg Se restored the normal architecture of the liver tissues. Furthermore, the 2 mg Se and DOX + 2 mg Se groups exhibited histologic changes including necrosis and degeneration of liver parenchyma. Our findings indicate that at low concentration, Se functions as an antioxidant, but at higher concentration it is a toxic pro-oxidant.

Cytokines are small molecular weight proteins that regulate cell survival, proliferation, differentiation, migration, immune cell activation and death. Cytokines are transcription factors required for gene regulation and activation of proinflammatory cytokines such as TNF-α and IL-1β (Caglayan et al. 2018). TNF-α initiates the cascade required for stimulation of cytokines, such as IL-1β, that are required for inflammation (Lee et al. 2008).

Induction of the inflammatory cascade appears to be the basis of Dox induced hepatotoxicity; DOX causes increased production of proinflammatory cytokines (Supriya et al. 2016), which is consistent with our finding that DOX caused a significant increase in tissue TNF-α and IL-1β levels associated with increased inflammatory cell infiltration of the hepatic tissues. These effects were ameliorated by the administration of Se.

We found minimal expression of inflammatory markers, TNF-α and IL1-β, in the liver of the DOX + 0.5 mg Se group. We also found significantly increased TNF-α in the hepatocytes of the 1 mg and 2 mg Se groups compared to the control group. Also, we found no decrease in IL1-β expression in the DOX + 1 mg Se and DOX + 2 mg Se treated groups compared to the DOX + 0.5 mg Se group.

PCNA is a nuclear protein that participates in the coordination of DNA replication and regulation of the cell cycle (Michalopoulos 2010). PCNA can be used to measure hepatic regenerative activity (Hellerbrand 2013), because it is expressed during early G1 and S phases of the cell cycle and functions in cell cycle progression, DNA replication and DNA repair (Kong et al. 2013; Lin et al. 2013). We found that PCNA expression increased in the DOX and DOX + 2 mg Se groups compared to all others; also, high dose Se did not change the number of PCNA positive cells.

Ours is the first report that different doses of Se can be protective against Dox induced liver damage. The protection afforded by Se might occur via cytokines to produce antioxidant enzymes. The antioxidant enzymes reverse Dox induced liver tissue damage. Se administered at a dose of 0.5 mg significantly attenuated the effects of DOX in rat liver. Our findings suggest that Se can be a protective adjuvant for DOX treatment when used at an appropriate dose. Our findings are consistent with reports that Se is an antioxidant with cytoprotective potential. We also confirmed that high doses of Se are toxic in vivo.

Disclosure statement

No potential conflict of interest was reported by the authors

Funding

Erciyes University is supported by the scientific research project unit TYL-2018-8365 [8365].

References

Alshabanah OA, Hafez MM, Al-Harbi MM, Hassan ZK, Al Rejaie SS, Asiri YA, Sayed-Ahmed MM. 2010. Doxorubicin toxicity can be ameliorated during antioxidant L-carnitine supplementation. Oxid Med Cell Longev. 3:428–433. doi:10.4161/oxim.3.6.14416

Ascensao A, Oliveira PJ, Magalhaes J. 2012. Exercise as a beneficial adjunct therapy during doxorubicin treatment–role of mitochondria in cardioprotection. Int J Cardiol. 156:4–10. doi:10.1016/j.ijcard.2011.05.060

Bardia A, Tleyjeh IM, Cerhan JR, Sood AK, Limburg PJ, Erwin PJ, Montori VM. 2008. Efficacy of antioxidant supplementation in reducing primary cancer incidence and mortality: systematic review and meta-analysis. Mayo Clin Proc. 83:23–34. doi:10.4065/83.1.23

Barogi S, Baracca A, Cavazzoni M, Parenti Castelli G, Lenaz G. 2000. Effect of the oxidative stress induced by adriamycin on rat hepatocyte bioenergetics during ageing. Mech Ageing Dev. 113:1–21. doi:10.1016/s0047-6374(99)00089-5

Bordoni A, Danesi F, Malaguti M, Di Nunzio M, Pasqui F, Maranesi M, Biagi PL. 2008. Dietary selenium for the counteraction of oxidative damage: fortified foods or supplements? Br J Nutr. 99:191–197. doi:10.1017/S0007114507793911

Bulucu F, Ocal R, Karadurmus N, Sahin M, Kenar L, Aydin A, Oktenli C, Koc B, Inal V, Yamanel L, Yaman H. 2009. Effects of N-acetylcysteine, deferoxamine and selenium on doxorubicin-induced hepatotoxicity. Biol Trace Elem Res. 132:184–196. doi:10.1007/s12011-009-8377-y

Caglayan C, Temel Y, Kandemir FM, Yildirim S, Kucukler S. 2018. Naringin protects against cyclophosphamide-induced hepatotoxicity and nephrotoxicity through modulation of oxidative stress, inflammation, apoptosis, autophagy, and DNA damage. Env Sci Pollut Res Int. 25:20968–20984. doi:10.1007/s11356-018-2242-5

Coers W, Huitema S, van der Horst ML, Weening JJ. 1994. Puromycin aminonucleoside and adriamycin disturb cytoskeletal and extracellular matrix protein organization, but not protein synthesis of cultured glomerular epithelial cells. Exp Nephrol. 2:40–50.

EI-Sayyad HI, Ismail MF, Shalaby FM, Abou-EI-Magd RF, Gaur RL, Fernando A, Raj MH, Ouhtit A. 2009. Histopathological effects of cisplatin, doxorubicin and 5-flurouracil (5-FU) on the liver of male albino rats. Int J Biol Sci. 5:466–473. doi:10.7150/ijbs.5.466

Flora SJ, Kannan GM, Pant BP, Jaiswal DK. 2002. Combined administration of oxalic acid, succimer and its analogue for the reversal of gallium arsenide induced oxidative stress in rats. Arch Toxicol. 76:269–276. doi:10.1007/s00204-002-0347-5

Gao Y, Li X, Gao Q, Fan L, Jin H, Guo Y. 2019. Differential effects of olive oil, soybean oil, corn oil and lard oil on carbon tetrachloride-induced liver fibrosis in mice. Biosci Rep. 39:1–17. doi:10.1042/BSR20191913

Gewirtz DA. 1999. A critical evaluation of the mechanisms of action proposed for the antitumor effects of the anthracycline antibiotics adriamycin and daunorubicin. Biochem Pharmacol. 57:727–741. doi:10.1016/s0006-2952(98)00307-4

Hellerbrand C. 2013. Hepatic stellate cells–the pericytes in the liver. Pflugers Arch. 465:775–778. doi:10.1007/s00424-012-1209-5

Huang Z, Rose AH, Hoffmann PR. 2012. The role of selenium in inflammation and immunity: from molecular

mechanisms to therapeutic opportunities. Antiox Redox Sign. 16:705–743. doi:10.1089/ars.2011.4145

Hui H, Ma W, Cui J, Gong M, Wang Y, Zhang Y, He T, Bi Y, He Y. 2017. Periodic acid-Schiff staining method for function detection of liver cells is affected by 2% horse serum in induction medium. Mol Med Rep. 16:8062–8068. doi:10.3892/mmr.2017.7587

Ingawale DK, Mandlik SK, Naik SR. 2014. Models of hepatotoxicity and the underlying cellular, biochemical and immunological mechanism(s): a critical discussion. Env Toxicol Pharmacol. 37:118–133. doi:10.1016/j.etap.2013.08.015

Jia X, Liu Q, Zou S, Xu X, Zhang L. 2015. Construction of selenium nanoparticles/beta-glucan composites for enhancement of the antitumor activity. Carbohydr Polym. 117:434–442. doi:10.1016/j.carbpol.2014.09.088

Jung HA, Kim JI, Choung SY, Choi JS. 2014. Protective effect of the edible brown alga *Ecklonia stolonifera* on doxorubicin-induced hepatotoxicity in primary rat hepatocytes. J Pharm Pharmacol. 66:1180–1188. doi:10.1111/jphp.12241

Kart A, Cigremis Y, Karaman M, Ozen H. 2010. Caffeic acid phenethylester (CAPE) ameliorates cisplatin-induced hepatotoxicity in rabbit. Exp Toxicol Pathol. 62:45–52. doi:10.1016/j.etp.2009.02.066

Kong BH, Shin HD, Kim SH, Mok HS, Shim JK, Lee JH, Shin HJ, Huh YM, Kim EH, Park EK, Chang JH, Kim DS, Hong YK, Kim SH, Lee SJ, Kang SG. 2013. Increased in vivo angiogenic effect of glioma stromal mesenchymal stem-like cells on glioma cancer stem cells from patients with glioblastoma. Int J Oncol. 42:1754–1762. doi:10.3892/ijo.2013.1856

Lance P, Alberts DS, Thompson PA, Fales L, Wang F, San Jose J, Jacobs ET, Goodman PJ, Darke AK, Yee M, Minasian L, Thompson IM, Roe DJ. 2017. Colorectal adenomas in participants of the SELECT randomized trial of selenium and vitamin E for prostate cancer prevention. Cancer Prev Res. 10:45–54. doi:10.1158/1940-6207.CAPR-16-0104

Lee HS, Jung KH, Hong SW, Park IS, Lee C, Han HK, Lee DH, Hong SS. 2008. Morin protects acute liver damage by carbon tetrachloride (CCl(4)) in rat. Arch Pharm. Res. (Seoul). 31:160–1165. doi:10.1007/s12272-001-1283-5

Lin W, Zheng L, Zhuang Q, Zhao J, Cao Z, Zeng J, Lin S, Xu W, Peng J. 2013. *Spica prunellae* promotes cancer cell apoptosis, inhibits cell proliferation and tumor angiogenesis in a mouse model of colorectal cancer via suppression of stat3 pathway. BMC Comple Alt Med. 24:13:144. doi:10.1186/1472-6882-13-144.

Mansouri E, Jangaran A, Ashtari A. 2017. Protective effect of pravastatin on doxorubicin-induced hepatotoxicity. Bratisl Lek Listy. 118:273–277. doi:10.4149/BLL2017054

Martinet Lamas DJ, Nicoud MB, Sterle HA, Carabajal E, Tesan F, Perazzo JC, Rivera ES, Medina VA. 2015. Selective cytoprotective effect of histamine on doxorubicin induced hepatic and cardiac toxicity in animal models. Cell Death Discov. 1:150–159. doi:10.1038/cddiscovery.2015.59

Mazevet M, Moulin M, Llach-Martinez A, Chargari C, Deutsch E, Gomez AM, Morel E. 2013. Complications of chemotherapy, a basic science update. Presse Med. 42:352–361. doi:10.1016/j.lpm.2013.06.011

Mete R, Oran M, Topcu B, Oznur M, Seber ES, Gedikbasi A, Yetisyigit T. 2016. Protective effects of onion (*Allium cepa*) extract against doxorubicin-induced hepatotoxicity in rats. Toxicol Ind Health. 32:551–557. doi:10.1177/0748233713504807

Michalopoulos GK. 2010. Liver regeneration after partial hepatectomy: critical analysis of mechanistic dilemmas. Am J Pathol. 176:2–13. doi:10.2353/ajpath.2010.090675

Minoti G, Menna P, Salvatorelli E, Cairo G, Gianni L. 2004. Anthracyclines: molecular advances and pharmacologic development in antitumor activity and cardiotoxicity. Pharmacol Rev. 56:185–229. doi:10.1124/pr.56.2.6

Mocchegiani E, Costarelli L, Giacconi R, Malavolta M, Basso A, Piacenza F, Ostan R, Cevenini E, Gonos ES, Monti D. 2014. Micronutrient-gene interactions related to inflammatory/immune response and antioxidant activity in ageing and inflammation. A Systematic Review. Mech Ageing. Dev.137:29–49. doi:10.1016/j.mad.2013.12.007

Mohan M, Kamble S, Satyanarayana J, Reddy N. 2011. Protective effect of *Solanum torvum* on doxorubicin-induced hepatotoxicity in rats. Int J Drug Dev. Res. 3:131–138. doi:10.1016/j.fct.2009.10.042

Nagai K, Fukuno S, Oda A, Konishi H. 2016. Protective effects of taurine on doxorubicin-induced acute hepatotoxicity through suppression of oxidative stress and apoptotic responses. Anticancer Drugs. 27:17–23. doi:10.1097/CAD.0000000000000299

Ognjanovic BI, Djordjevic NZ, Matic MM, Obradovic JM, Mladenovic JM, Stajn AS, Saicic ZS. 2012. Lipid peroxidative damage on cisplatin exposure and alterations in antioxidant defense system in rat kidneys: a possible protective effect of selenium. Int J Mol Sci. 13:1790–1803. doi:10.3390/ijms13021790

Paczek L, Teschner M, Schaefer RM, Kovar J, Romen W, Heidland A. 1992. Intraglomerular proteinase activity in adriamycin-induced nephropathy. Nephron. 60:81–86. doi:10.1159/000186709

Patel N, Joseph C, Corcoran GB, Ray SD. 2010. Silymarin modulates doxorubicin-induced oxidative stress, Bcl-xL and p53 expression while preventing apoptotic and necrotic cell death in the liver. Toxicol Appl Pharmacol. 245:143–152. doi:10.1016/j.taap.2010.02.002

Pereira GC, Pereira SP, Pereira CV, Lumini JA, Magalhaes J, Ascensao A, Santos MS, Moreno AJ, Olivera PJ. 2012. Mitochondrionopathy phenotype in doxorubicin-treated Wistar rats depends on treatment protocol and is cardiac specific. PLoS One. 7:e38867. doi:10.1371/journal.pone.0038867

Rashid S, Ali N, Nafees S, Ahmad ST, Arjumand W, Hasan SK, Sultana S. 2013. Alleviation of doxorubicin-induced nephrotoxicity and hepatotoxicity by chrysin in Wistar rats. Toxicol. Mech. Methods. 23:337–345. doi:10.3109/15376516.2012.759306

Rayman MP. 2002. The argument for increasing selenium intake. Proc Nutr Soc. 61:203–215. doi:10.1079/PNS2002153

Saad SY, Najjar TA, Al-Rikabi AC. 2001. The preventive role of deferoxamine against acute doxorubicin ınduced cardiac, renal and hepatic toxicity in rats. Pharmacol Res. 43:211–218. doi:10.1006/phrs.2000.0769

Simoni J, Simoni G, Garcia EL, Prien SD, Tran RM, Feola M, Shires GT. 1995. Protective effect of selenium on hemoglobin mediated lipid peroxidation in vivo. Artif Cells Blood Subst Immobil Biotechnol. 23:469–486. doi:10.3109/10731199509117963.

Soudani N, Ben Amara I, Sefi M, Boudawara T, Zeghal N. 2011. Effects of selenium on chromium (VI)-induced hepatotoxicity in adult rats. Exp Toxicol Pathol. 63:541–548. doi:10.1016/j.etp.2010.04.005

Stajn A, Zikic RV, Ognjanovic B, Saicic ZS, Pavlovic SZ, Kostic MM, Petrovic VM. 1997. Effect of cadmium and selenium on the antioxidant defence system in rat kidneys. Comp Biochem Physiol C. 117:167–172. doi:10.1016/s0742-8413(97)00063-7.

Stehbens WE. 2003. Oxidative stress, toxic hepatitis, and antioxidants with particular emphasis on zinc. Exp Mol Pathol. 75:265–276. doi:10.1016/s0014-4800(03)00097-2

Stemm DN, Tharappel JC, Lehmler HJ, Srinivasan C, Morris JS, Spate VL, Robertson LW, Spear BT, Glauert HP. 2008. Effect of dietary selenium on the promotion of hepatocarcinogenesis by 3,3′, 4,4′-tetrachlorobiphenyl and 2,2′, 4,4′, 5,5′-hexachlorobiphenyl. Exp Biol Med. 233:366–376. doi:10.3181/0708-RM-211

Supriya R, Tam BT, Pei XM, Lai CW, Chan LW, Yung BY, Siu PM. 2016. Doxorubicin induces inflammatory modulation and metabolic dysregulation in diabetic skeletal muscle. Front Physiol. 7:323–336. doi:10.3389/fphys.2016.00323

Tacar O, Sriamornsak P, Dass CR. 2013. Doxorubicin: an update on anticancer molecular action, toxicity and novel drug delivery systems. J Pharm Pharmacol. 65:157–170. doi:10.1111/j.2042-7158.2012.01567.x

Takahashi K, Newburger PE, Cohen HJ. 1986. Glutathione peroxidase protein. Absence in selenium deficiency states and correlation with enzymatic activity. J Clin Invest. 77:1402–1404. doi:10.1172/JCI112449

Tangpong J, Miriyala S, Noel T, Sinthubulyakit C, Jungsuwadee P, St. Clair DK. 2011. Doxorubicin induced central nervous system toxicity and protection by xanthone derivative of *Garcinia mangostana*. Neuroscience. 175:292–299. doi:10.1016/j.neuroscience.2010.11.007

Zhang Q, Chen L, Guo K, Zheng L, Liu B, Yu W, Guo C, Liu Z, Chen Y, Tang Z. 2013. Effects of different selenium levels on gene expression of a subset of selenoproteins and antioxidative capacity in mice. Biol Trace Elem Res. 154:255–261. doi:10.1007/s12011-013-9710-z